

# *High-Yield OMT for the Upper & Lower Extremities*

Shawn R. Kerger, DO, FAOASM

Associate Professor, OMM Dept, OU-HCOM – Dublin

Medical Director, OMM Department, Doctors Hospital

Medical Director, Peter E. Johnston, DO, Simulation & Education Center

- P. Gunnar Brolinson, DO, FAAFP, FAOASM
- Paul Tortland, DO, FAOASM
- Albert Kozar, DO, FAOASM
- Richard Schuster, DO



# Osteopathic Principles

- The Osteopathic principles proposed by AT Still which most directly relate to our purposes here are:
  - “When all parts of the body are in line we have health.”
  - “When complete, he is...in size & form to suit the duties he may have to perform.”
  - “You as Osteopathic machinists ...adjust the abnormal condition, in which you find the afflicted. Nature will do the rest.”



# Osteopathic Principles

- Or as restated by the faculty of the Kirksville College of Osteopathy & Surgery in 1953:
  - The body is a unit.
  - Structure & function are reciprocally interrelated.
  - The body is self-healing.




# Tensegrity

- Still in development
- A self-stabilizing system in which tension is continuously transmitted across all elements
- Stability from distribution & balancing of mechanical forces
- Triangulated structures form the basis for this system
  - Tetrahedron
  - Octahedron
  - Icosahedron



# Functional Anatomic Concepts: Muscle

- Kinetic chain - the sequencing of individual body segments & joints to accomplish a task
- Generally functions from a base of support proximally & then proceeds distally, but this is entirely dependant on the task at hand:
  - a bench press would follow the aforementioned path
  - a pushup reverses the mechanics even though the muscles engaged are similar, if not identical



## Kinetic Chain

- Sequence of engrams resulting in a motion
- ‘Catch-up’ phenomenon
  - compensation for dysfunction in the earlier (temporally speaking) components of the chain is not as productive a motion and can lead to injury in the later components, as the tissues either cannot handle the load or fire inappropriately
  - Kibler



# Compensation, Dysfunction, and Motor Patterns

- Compensation can be a good thing – allows for us to perform around a hindrance.
- Or, at times, it can result in dysfunction in which we are now impaired to a greater degree than the original hindrance!



[https://encrypted-tbn3.gstatic.com/images?q=tbn:ANd9GcTinDH-kMgLPNI-hLo8g5rMh9Mg-G-GkmpvejBS\\_NaLUJEeRog7-g](https://encrypted-tbn3.gstatic.com/images?q=tbn:ANd9GcTinDH-kMgLPNI-hLo8g5rMh9Mg-G-GkmpvejBS_NaLUJEeRog7-g)



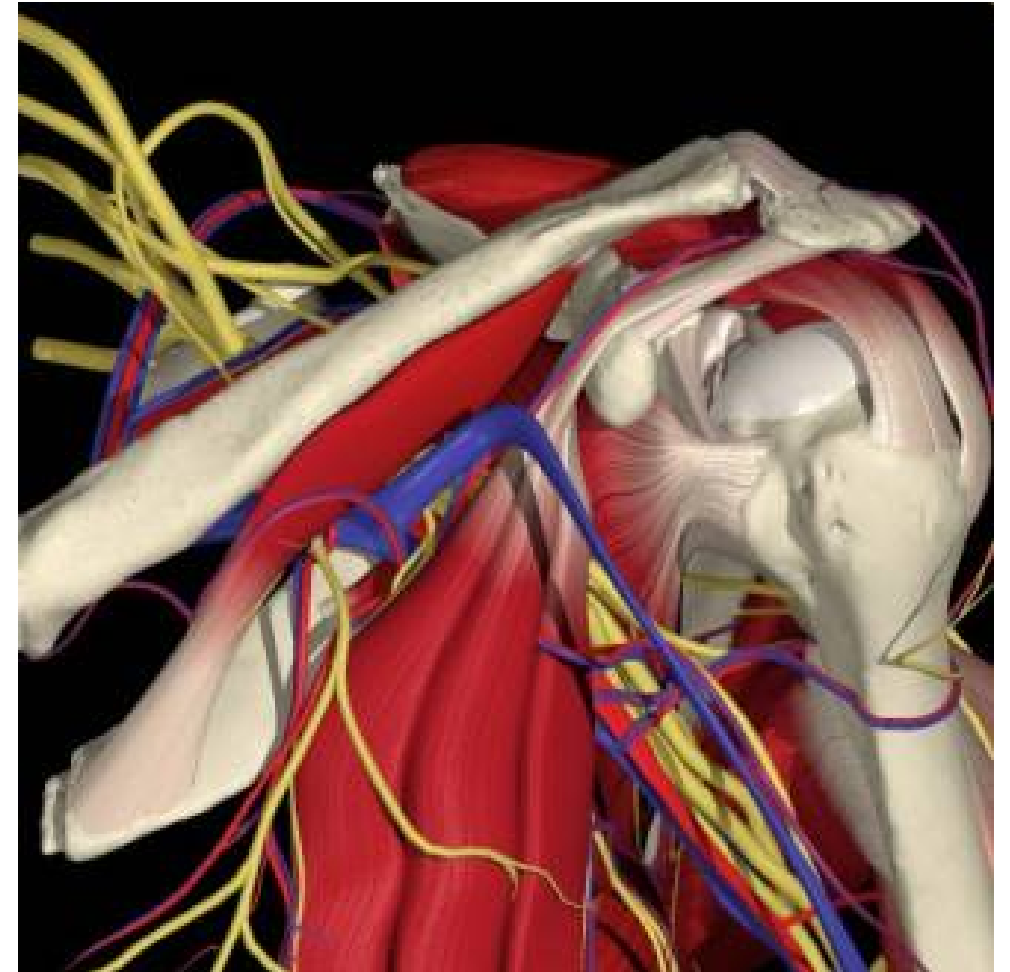## Disturbed Motor Function

- Most important symptom ...  
PAIN!
- The area of the pain may not tell you where the problem is...
- Must learn to identify & treat underlying somatic dysfunction.



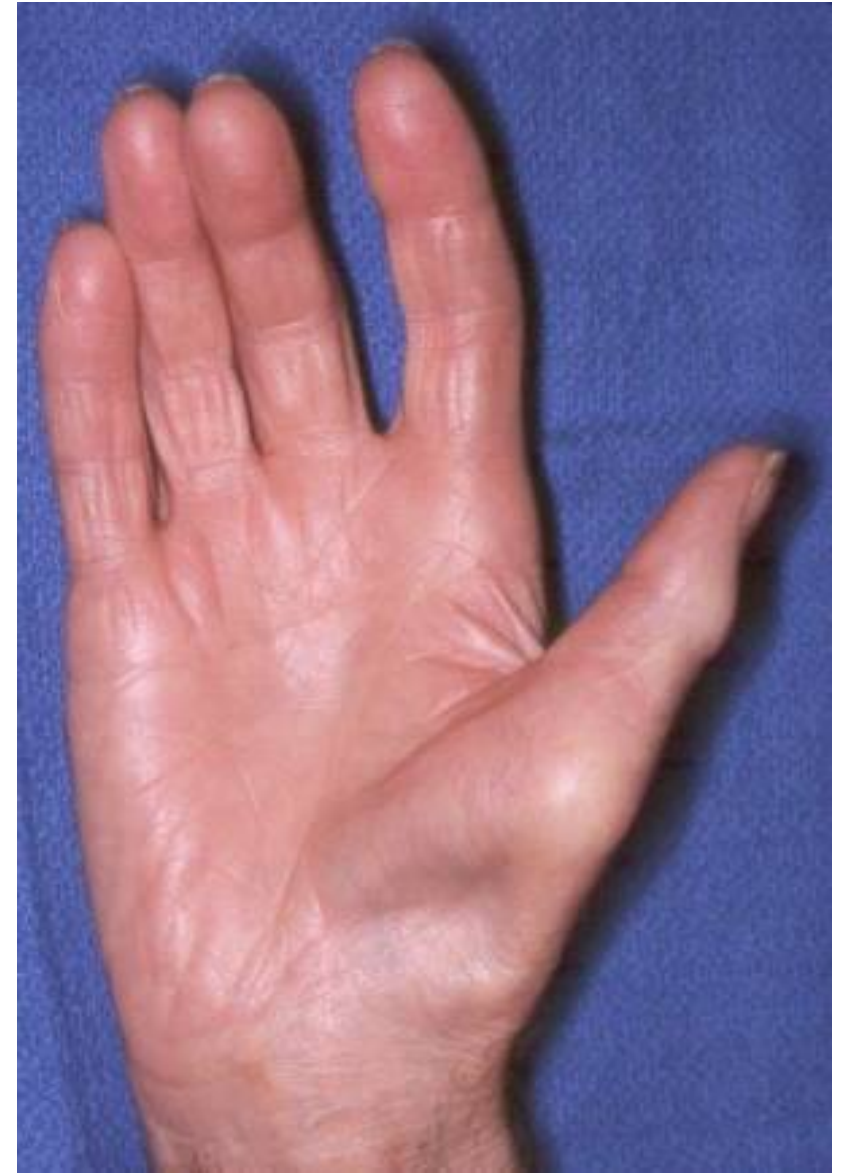# Somatic Dysfunction

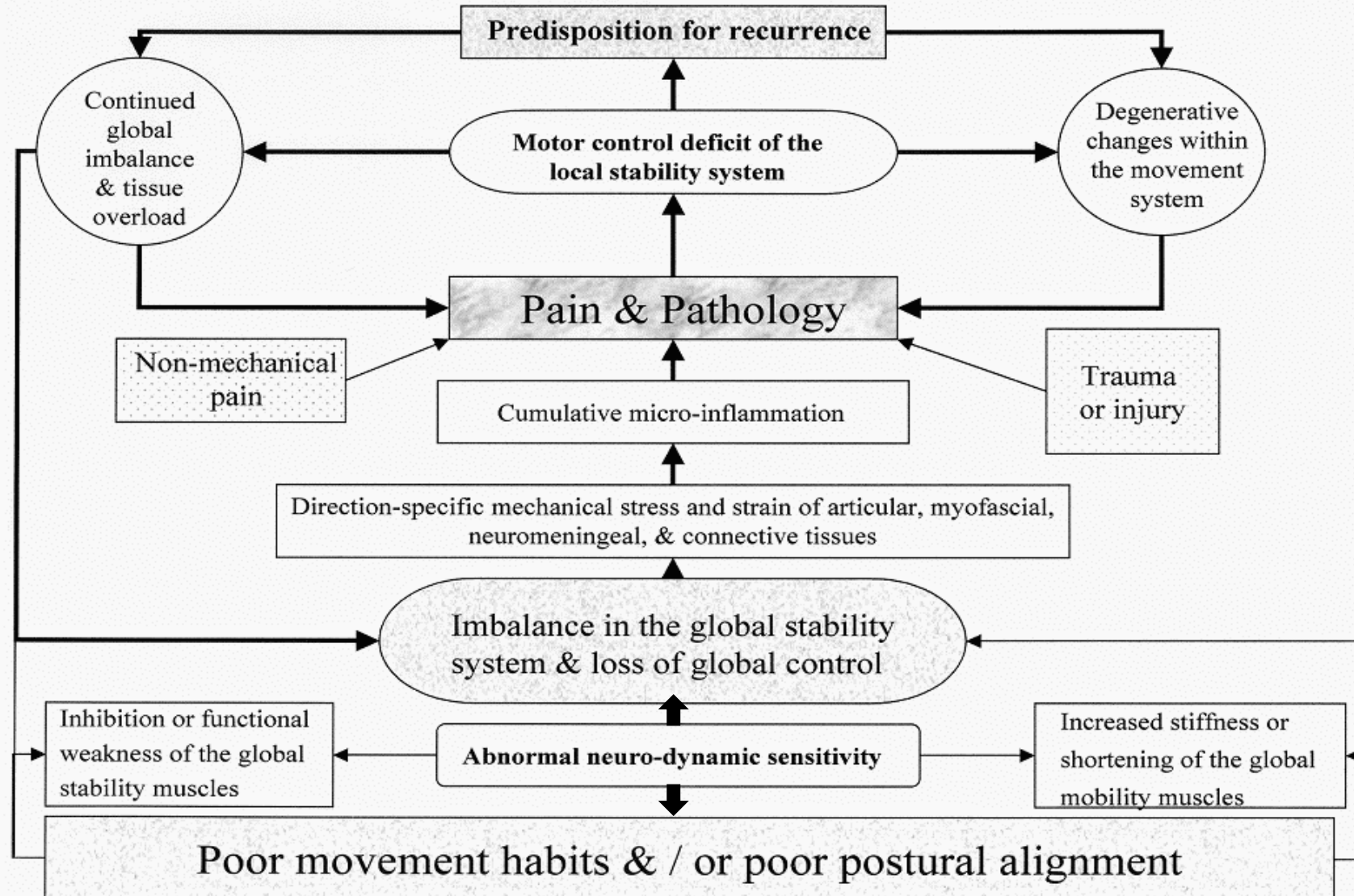
- Impaired or altered function of related components of the somatic (body framework) system: skeletal, arthrodiar, & myofascial structures, & related vascular, lymphatic, & neural elements.



# Dysfunction

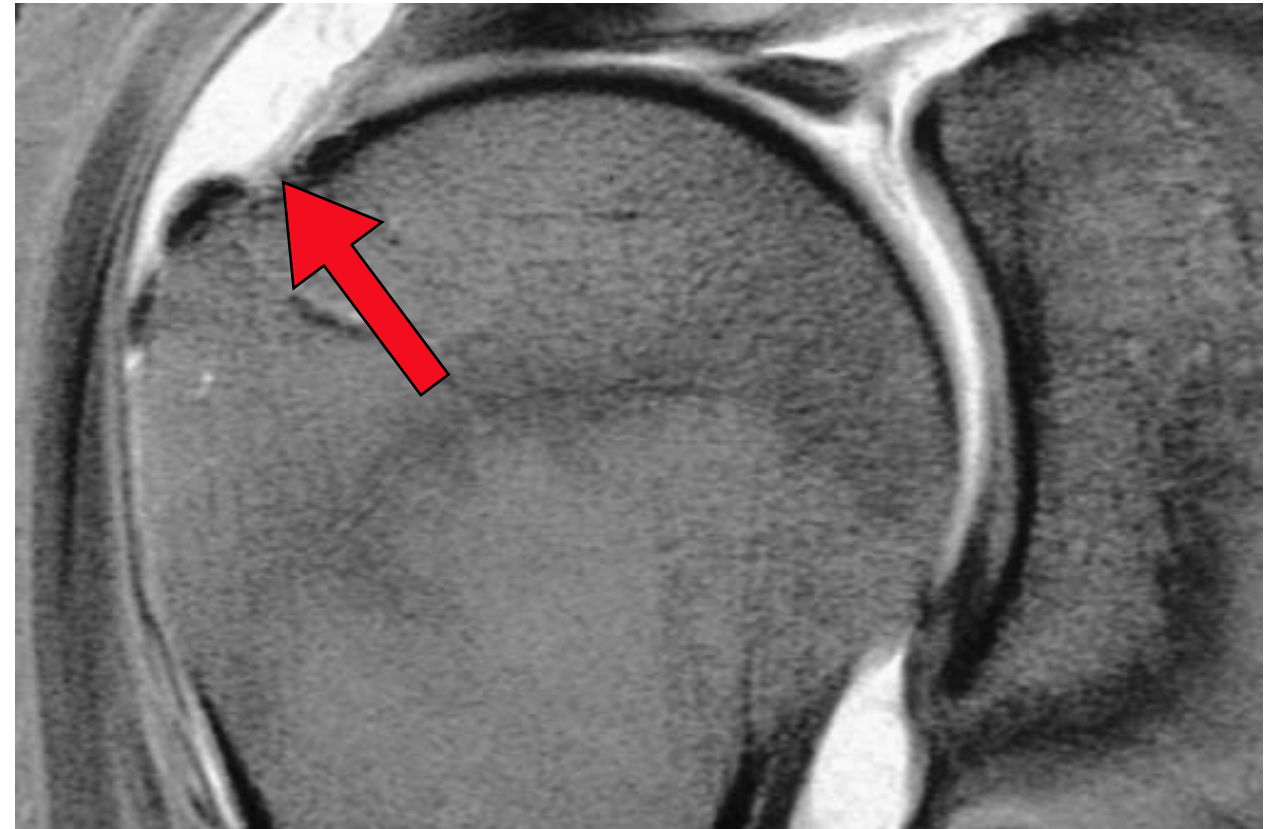
- Logically, lack of use of a tissue (either due to injury, improper pain management, altered or improper technique, joint or soft tissue restrictions, etc.) will reverse the normal physiological processes.
  - Bone will become less dense
  - Joints will stiffen & ligaments will shorten
  - Muscles will atrophy & neuromuscular control will be negatively altered
  - Metabolic processes will revert to a lower energy (basal metabolic rate will drop), yet less exercise-tolerant, condition





## Functional Biomechanical Exam

- We'll assume you know how to diagnose the “itis” pathologies
- Now that we know *where* the problem is, the issue becomes why is it there?



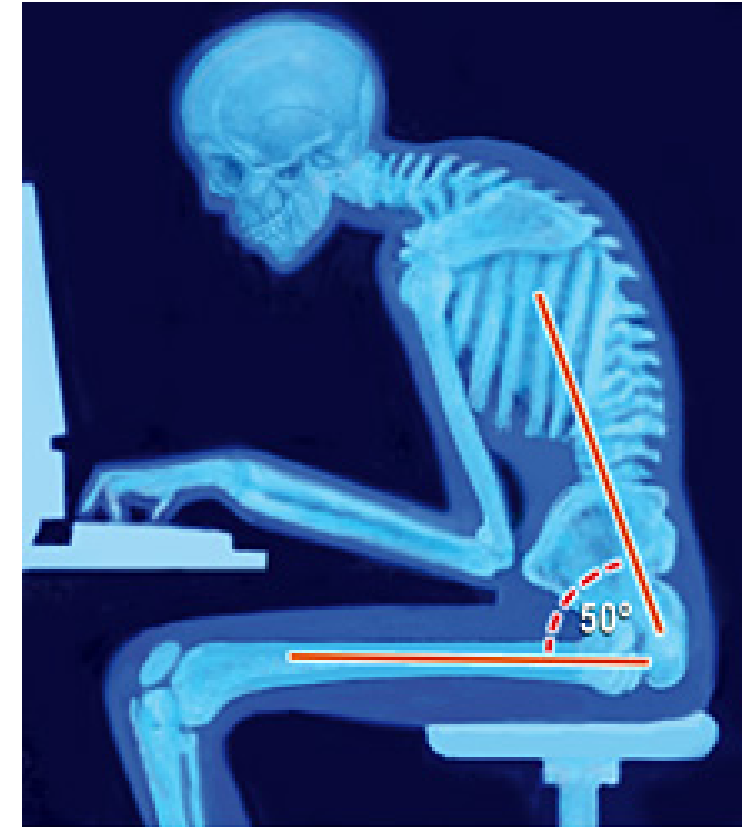# Gravitational Strain

- 3 Cardinal Bases of Support
  - The standing surface
  - The feet
  - The base of the sacrum



# Gravitational Strain

- 3 Cardinal Bases of Support
  - The standing surface
  - The feet
  - The base of the sacrum

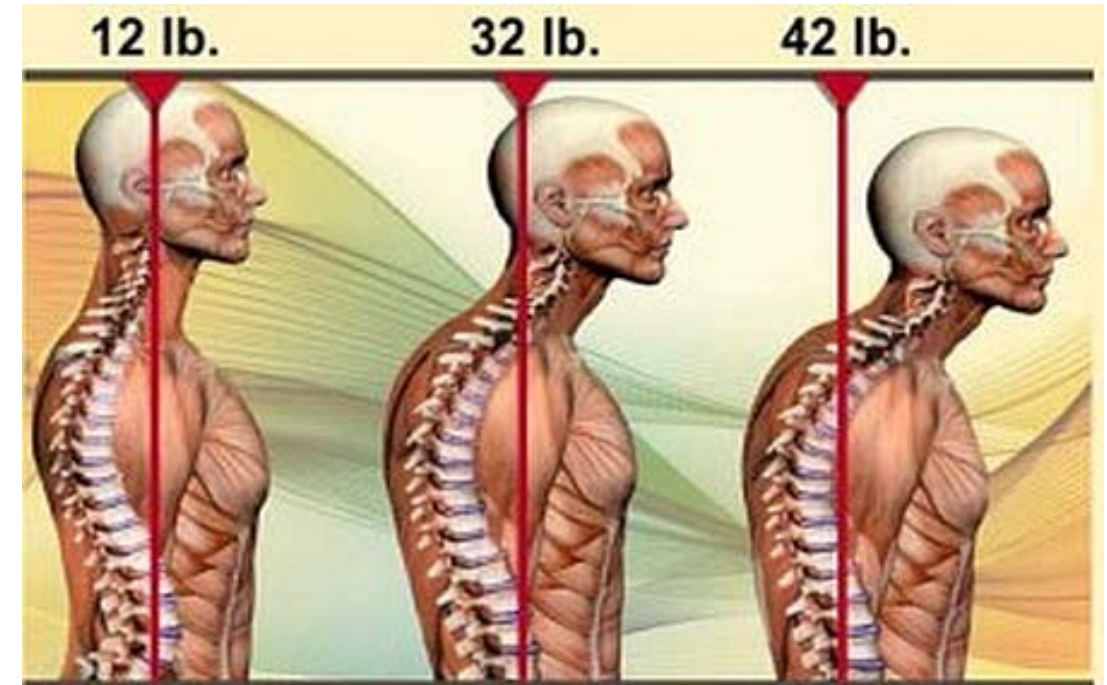


© 2011 www.erikdalton.com

<http://themethuselahcenter.com/wp-content/uploads/2011/07/poor-posture.jpg>

# Gravitational Strain

- Posture
  - Size , shape & attitude of the musculoskeletal system.
  - Departure from “ideal” posture results in increased mechanical stress.
  - Gravity *never* has an “off” day.



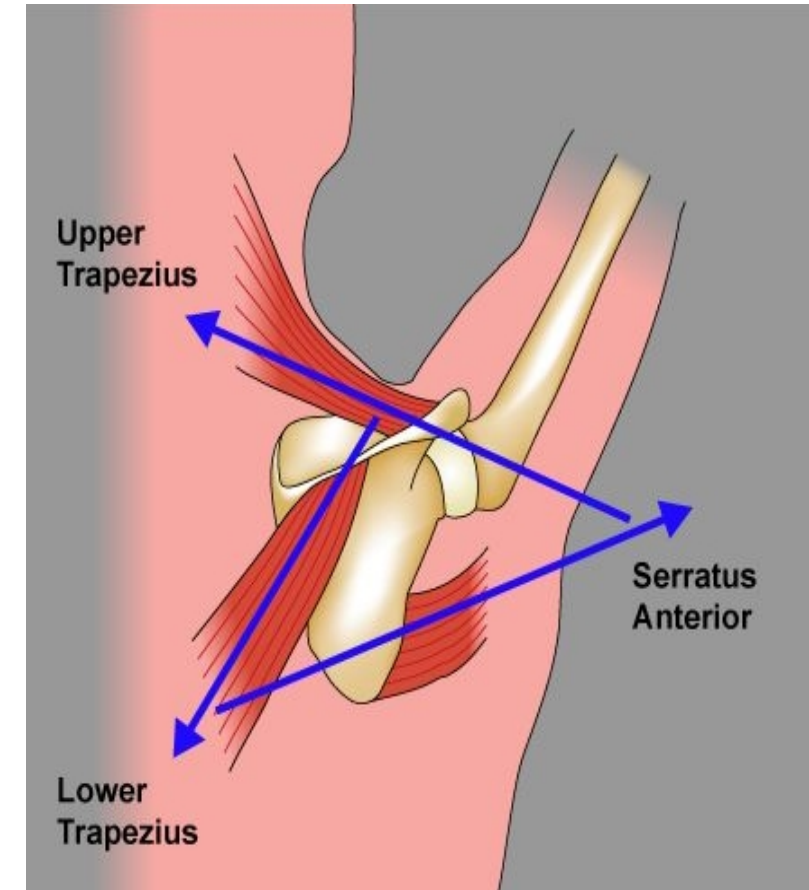
“For every inch of Forward Head Posture, it can increase the weight of the head on the spine by an additional 10 pounds.” Kapandji, Physiology of Joints, Vol. 3



# Upper Extremity

## SICK Scapula Syndrome (SSS)

- So coined by Craig Morgan as “SICK (Scapula Infera Coracoid dysKinesia) scapula syndrome”
- Collection of abnormal scapular mechanics that lead to repetitive microtrauma of the throwing motion, resulting in painful conditions of the shoulder due to muscle strain, fatigue and breakdown.
- Results in limited scapular retraction and acromial elevation with arm elevation, leading to subacromial impingement.



<http://davidlasnier.com/2012/overhead-work-and-shoulder-flexion-limitation>

## SICK Scapula Syndrome (SSS)

- Can develop from altered postures (see Upper Crossed Syndrome), repetitive microtrauma from poor technique, or atypical anatomy/firing patterns.
- Therefore, can be either causative or responsive to injury – so you need to be watchful both during diagnostic and treatment phases of patient care.
- If found, should be treated as it absolutely predisposes one to impingement syndrome – it no longer is a question of “If”, but “When”.

## SICK Scapula Syndrome (SSS)

- Hx: Symptoms above worsened by position or activity usually involving the upper extremity.
  - Might have vague symptoms (burning/aching after activity or prolonged postures) involving scapula, but these have usually been present for some time & the patient might not think of them as related.
  - Usually not associated by patient with trauma.
  - Pain is usually mild-moderate, but can be severe depending on structure under abnormal load (the SSS is usually asymptomatic itself).
  - No central neurologic symptoms.



<http://rpm-therapy.com/wp-content/uploads/2012/09/hairdresser-posture-bad3.jpg>

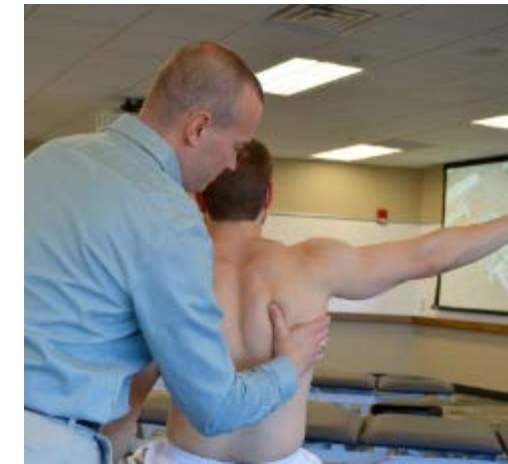
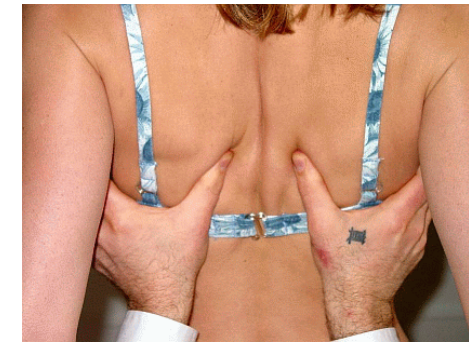
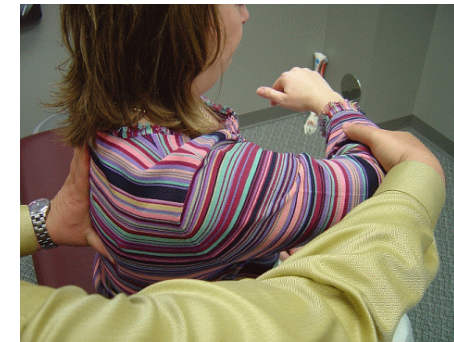
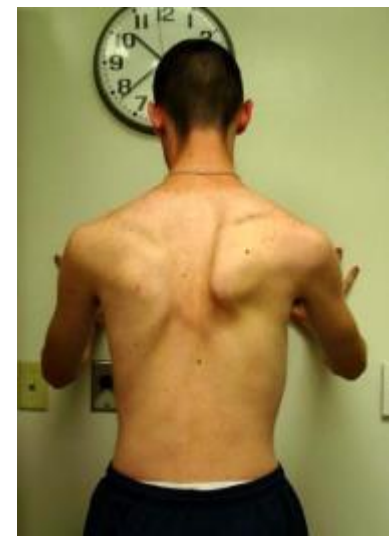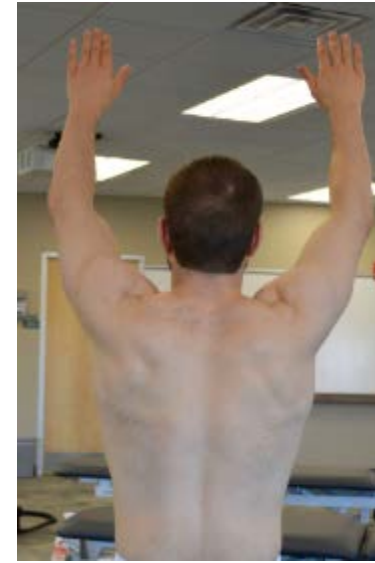<http://rpm-therapy.com/wp-content/uploads/2012/09/hairdresser-posture-bad.jpg>

# Diagnose your partner's scapular mechanics

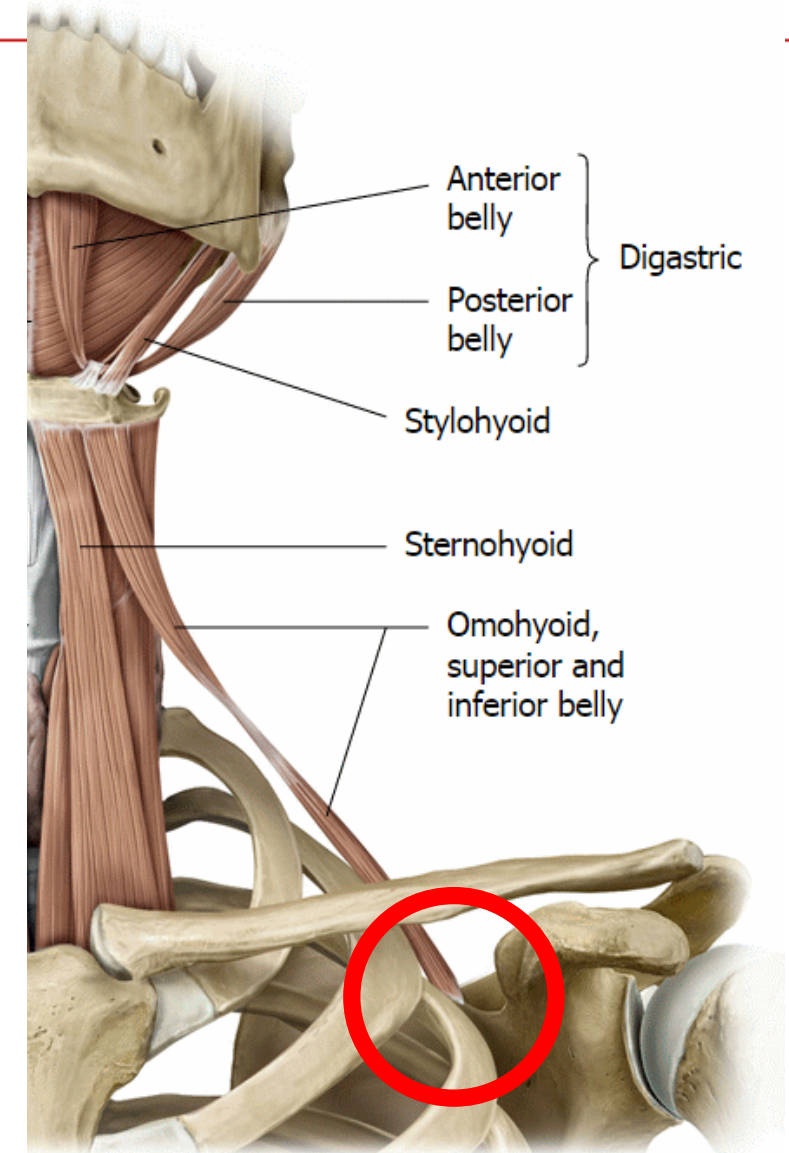
## Special Physical Examinations:

- Scapular resting position with arms:
  - At the side
  - Bent with hands on hips
  - At or below 90° of abduction w/ shoulders IR & forearms pronated
- Wall push-up (long thoracic palsy)
- Scapular motion comparison for shoulder flexion & abduction in both concentric & eccentric phases
- Scapular muscle strength
- Scapular assistance (examiner pushes inferior & medial border of scapula laterally and superiorly – or anteriorly at inferior angle if winging present)
- Glenohumeral PROM and end-feel



# SICK Scapula Syndrome (SSS)

- Osteopathic:
  - Altered mechanics ANYWHERE in the kinetic chain for throwing!
  - Findings of elevated 1<sup>st</sup> or 2<sup>nd</sup> rib, cervical or thoracic vertebral or muscular dysfunction, clavicular or scapular dysfunction all can be primary or secondary to the problem developing.
  - Frequently, tender/dysfunction levator scapula & upper traps – *if lev scapula dysfunction recurrent, consider omohyoid TP.*



# Osteopathic Treatment

- If warm, wet/oily, swollen, painful/tender tissues with spongy or boggy end-points are encountered, consider indirect techniques (FPR, SCS, Still's, OCF, etc.) as this is most likely an acute situation.
- If cool, dry, sore, ropy tissues with firmer/articular end-points are encountered, consider direct techniques (soft tissue, ME, HVLA/LVHA, etc.) as this is more of a chronic situation.
- Can always prep with indirect or soft tissue techniques before direct, too – you might just be wrong, and resolve the lesion with this!

# Osteopathic Treatment

- When the somatic dysfunction is corrected, recheck any orthopedic or other findings to see what has changed – anything that's left after correction of somatic dysfunction is concerning for tissue damage/inflammation.
- Pain is the LAST thing to go, usually – especially in the 8-72 hour period after an injury (or after you are poking and prodding the patient during physical examination) – so don't get focused on pain response as your most important measure for success.
- Get things moving properly, & the pain will follow...



# We're going to utilize this opportunity for upper quadrant treatment approach

- First, treat in a gravity reactive (or kinetic chain) pattern:
  - Contralateral lower extremity
  - Pelvis
  - Sacrum
  - Lumbar
  - Thorax
  - Ribs
  - Cervical
- Then, we'll start with the upper extremity...



[http://assets.nydailynews.com/polopoly\\_fs/1.4746701/img/httpImage/image.jpg\\_gen/derivatives/article\\_970/alg-rangers-lee-motion-jpg.jpg](http://assets.nydailynews.com/polopoly_fs/1.4746701/img/httpImage/image.jpg_gen/derivatives/article_970/alg-rangers-lee-motion-jpg.jpg)

# We're going to utilize this opportunity for upper quadrant treatment approach

- Work proximally to distally:
  - Scapulothoracic joint
  - Glenohumeral joint (see Spencer Technique)
  - Elbow – both humeroulnar & radial head
  - Wrist
  - Hand

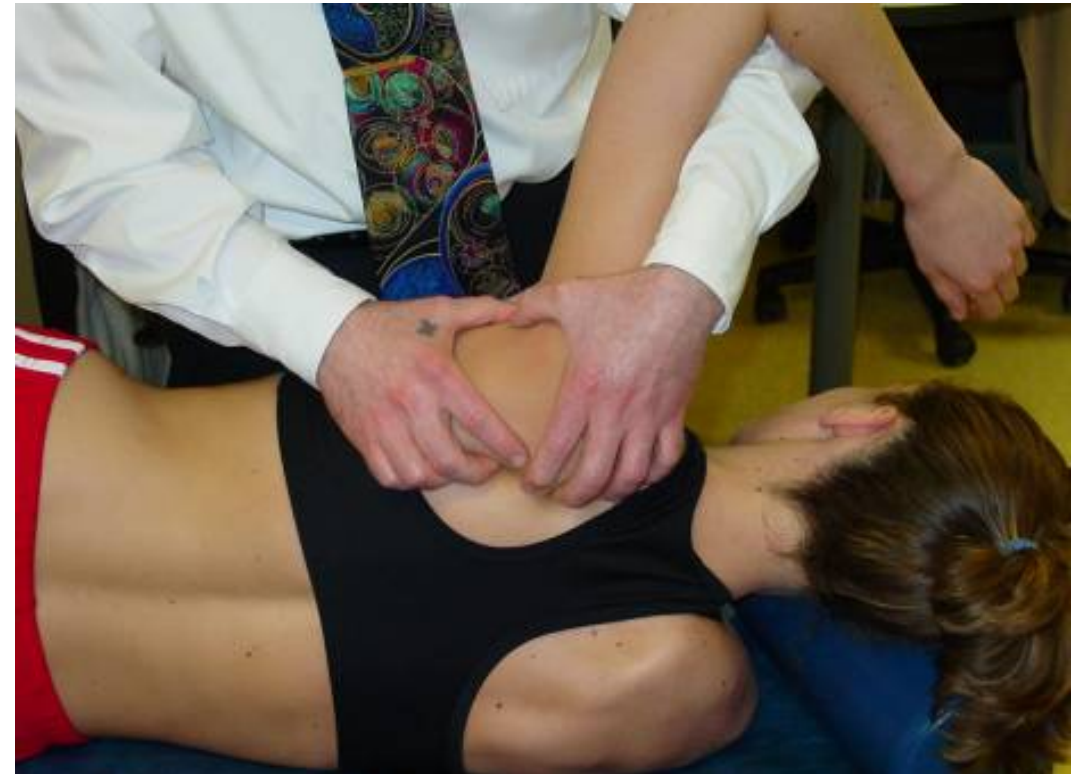

[http://assets.nydailynews.com/polopoly\\_fs/1.474670!/img/httpImage/image.jpg\\_gen/derivatives/article\\_970/alg-rangers-lee-motion-jpg.jpg](http://assets.nydailynews.com/polopoly_fs/1.474670!/img/httpImage/image.jpg_gen/derivatives/article_970/alg-rangers-lee-motion-jpg.jpg)

# Scapulothoracic Joint

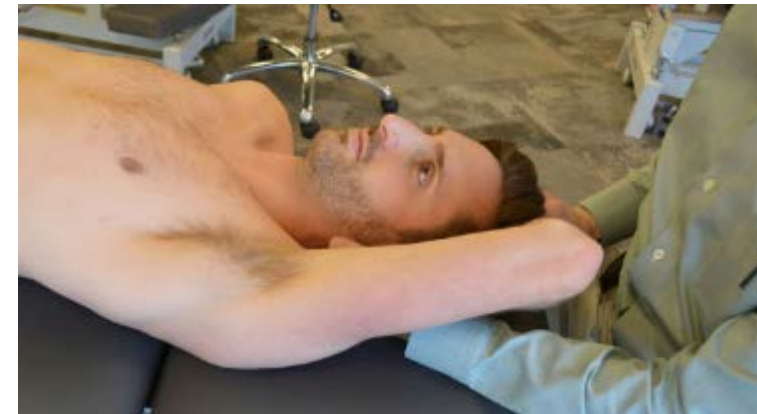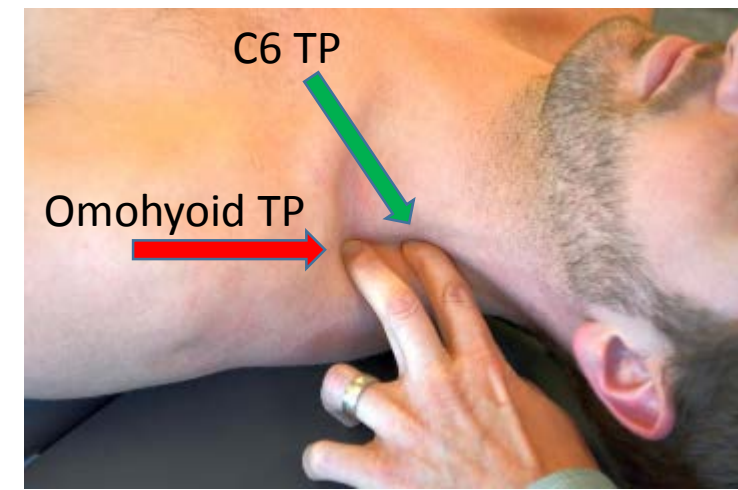
# Myofascial Release – Scapulothoracic lesion

- Pt is in lateral recumbent with affected side up
- Grasp scapula along medial and lateral borders.
- Can do:
  - Direct or indirect myofascial release
  - Direct stretch against restriction
  - Muscle Energy



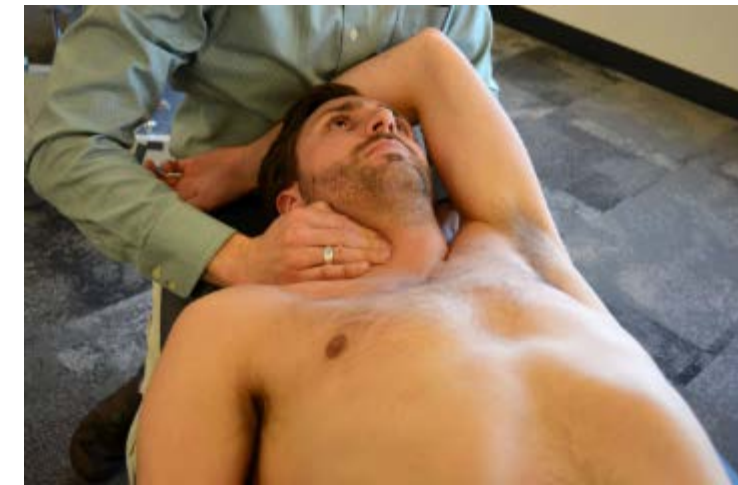# Omohyoid Tenderpoint – SCS

- Need to set up to treat C<sub>6</sub> TP first – once in proper position for at least 70% pain relief (see picture 2, might need some slight refinement), then you set up for the omohyoid TP.
- With the flats of as many fingers as you can evenly distribute across the larynx and proximal trachea, deviate the laryngeal complex toward the side of the lesion.
- Follow typical SCS protocol from there.



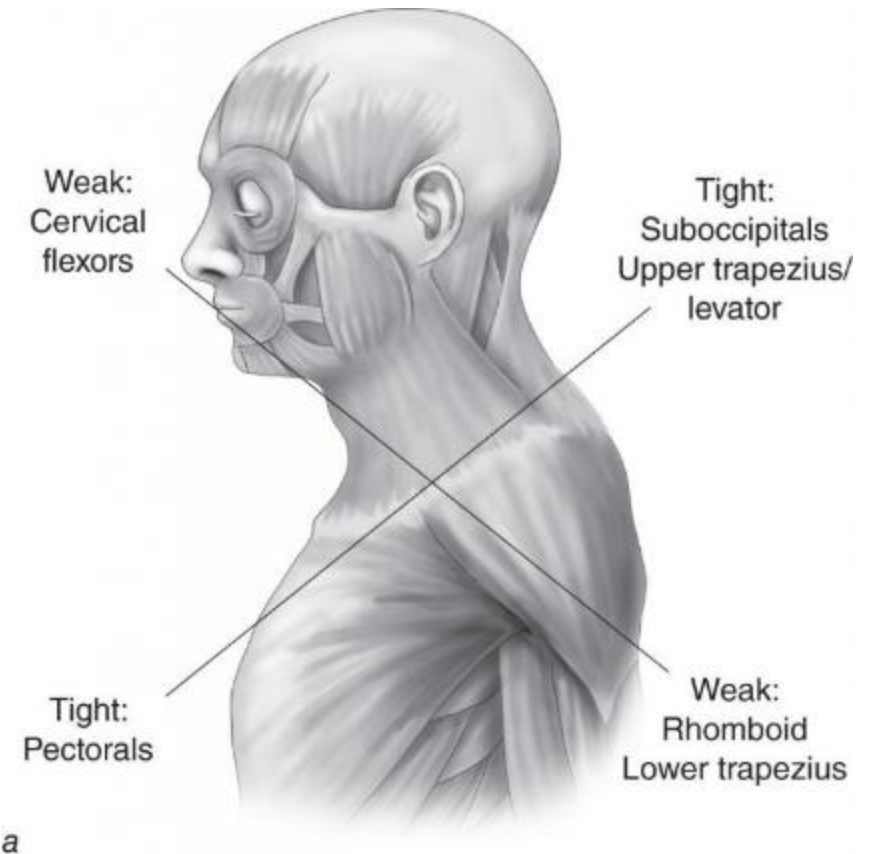
C<sub>6</sub> TP SCS position

Omohyoid SCS position



## Upper Crossed Syndrome (UCS)

- Tight pectorals & upper traps inhibit deep 4<sup>th</sup> layer cervical flexors & lower traps.
- Results in kyphotic thorax w/ internally rotated / protracted scapulae, & lordotic cervicals.
- Leads to impingement syndromes & cervical / upper thoracic complaints.

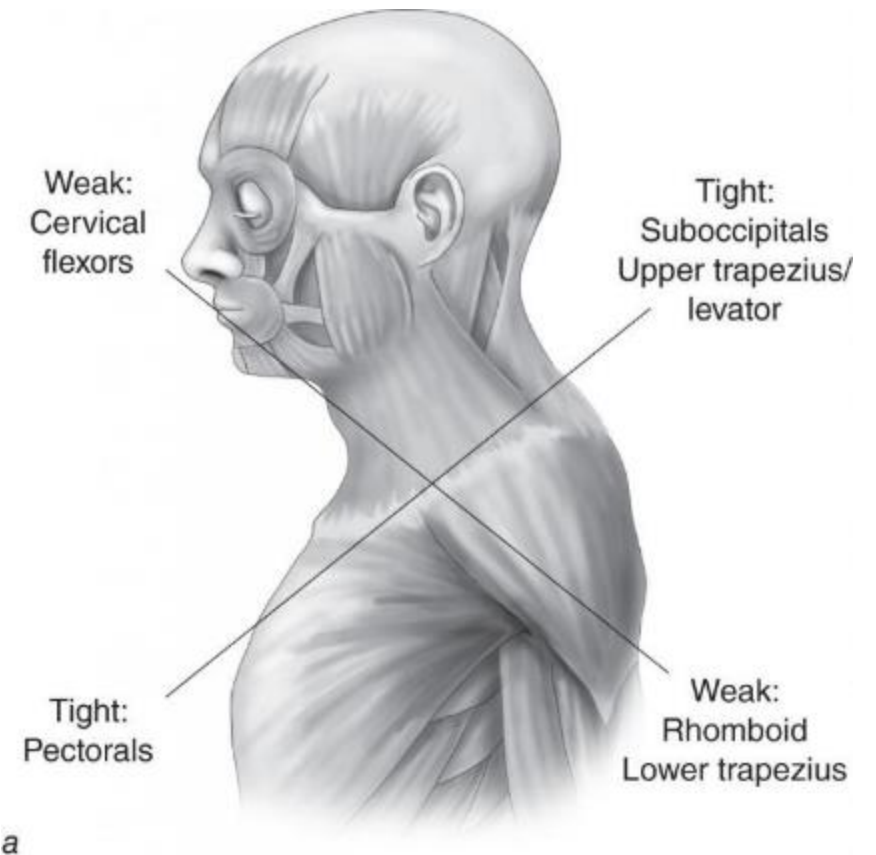


©Human Kinetics 2010

<http://www.muscleimbalancesyndromes.com/janda-syndromes/upper-crossed-syndrome/>

# Upper Crossed Syndrome (UCS)

- In order to diagnose UCS, you find:
  - Tight pairs of pectorals & upper traps / suboccipital muscles
  - Inhibited cervical flexors & lower traps / rhomboids
  - Altered scapular kinetics that are reversible with correction of the above.
- You MAY also have a tight anterior G-H capsule, setting up an arthrokinetic reflex.



©Human Kinetics 2010

<http://www.muscleimbalancesyndromes.com/janda-syndromes/upper-crossed-syndrome/>

## UCS – Arthrokinetic Reflex

- Capsule or ligament becomes stretched beyond what its programming allows for as a normal ROM (or if too rapid a motion occurs), inhibitory signals are sent to the agonist muscle responsible for loading the joint in the plane in question & stimulatory signals to the antagonist musculature.





## UCS – Arthrokinetic Reflex

- E.g., Anterior shoulder capsule is stretched more than its programming allows:
  - Lower trap muscles receive an inhibitory signal
  - Pectoralis muscles will be stimulated.
- This is the case in both healthy and dysfunctional states, with the difference being when this process is activated.
- Will *prevent* normal stretching...



## Upper Crossed Syndrome - UCS

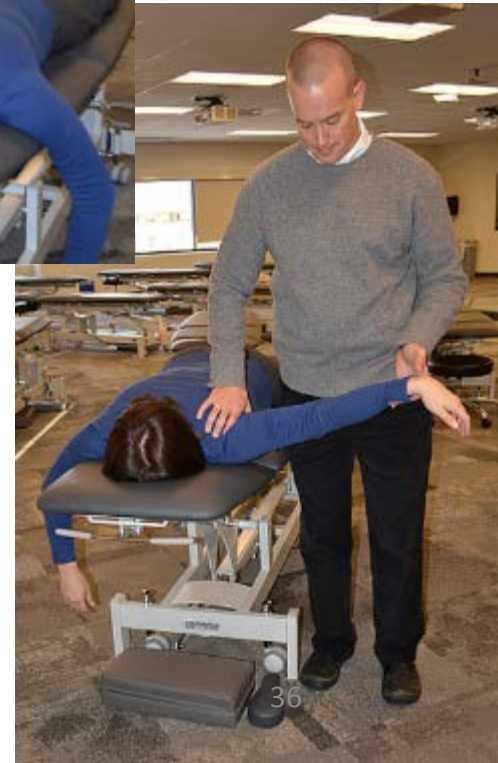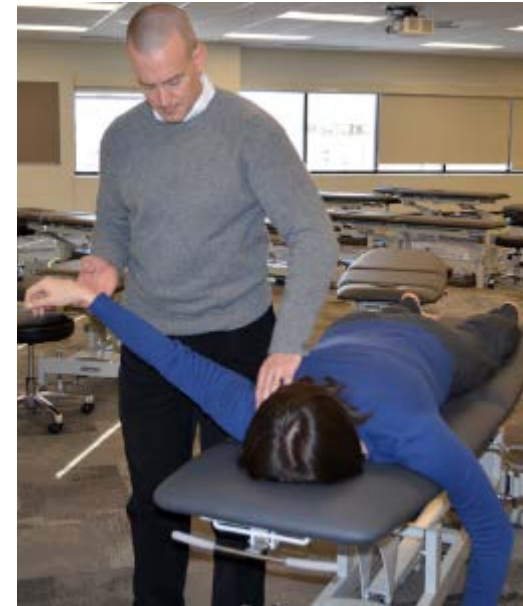
- Hx: Pain is rarely present with this – until something else breaks down...will present as RTC tendonitis, MTHA, periscapular pain, etc.
- Hx will be consistent with the presenting complaint, so you have to go looking for this – although it's NOT hard to find.
- Also useful for athletes who are without complaint, but struggling to make an improvement or are having more general symptoms (“can’t move like I used to” or “I’m getting hurt all the time now with lots of little injuries”, etc.)
- This is absolutely a preventable situation and you should consider including in all your routine physicals...it’s osteopathic!

## Upper Crossed Syndrome (UCS) – Physical Exam

- Check scapular ROM to flexion and abduction – look for:
  - ROM
  - Congruity of motions b/n scapulae
  - Firing patterns of upper trap vs. lower and middle trap
  - Winging of scapula
  - Pain reports
- If abnormal, or your index of suspicion based on history is high – then check for anterior shoulder capsule restriction (arthrokinetic reflex early activation)

## UCS – Physical Exam

- Stabilize the scapula posteriorly
- Horizontally abduct the arm at 90 degrees of abduction with the elbow extended
- Should get 40-45 degrees of horizontal abduction, minimum
- Also evaluate the end-feel...



## Upper Crossed Syndrome - UCS

- Osteopathic:
  - Nearly always kyphotic in thorax, but might also have flattened thoracic spine with more dramatic anterior head carriage.
  - If acute, usually painful ROM limitations are in 1-2 planes and the midline may be shifted. Spinal/postural responses are large and rudimentary (vs. chronic in which multiple A-P and lateral curves have developed over time to accommodate).
  - If chronic, variable postural or mechanical difficulties can be present and might even be maintaining the syndrome.

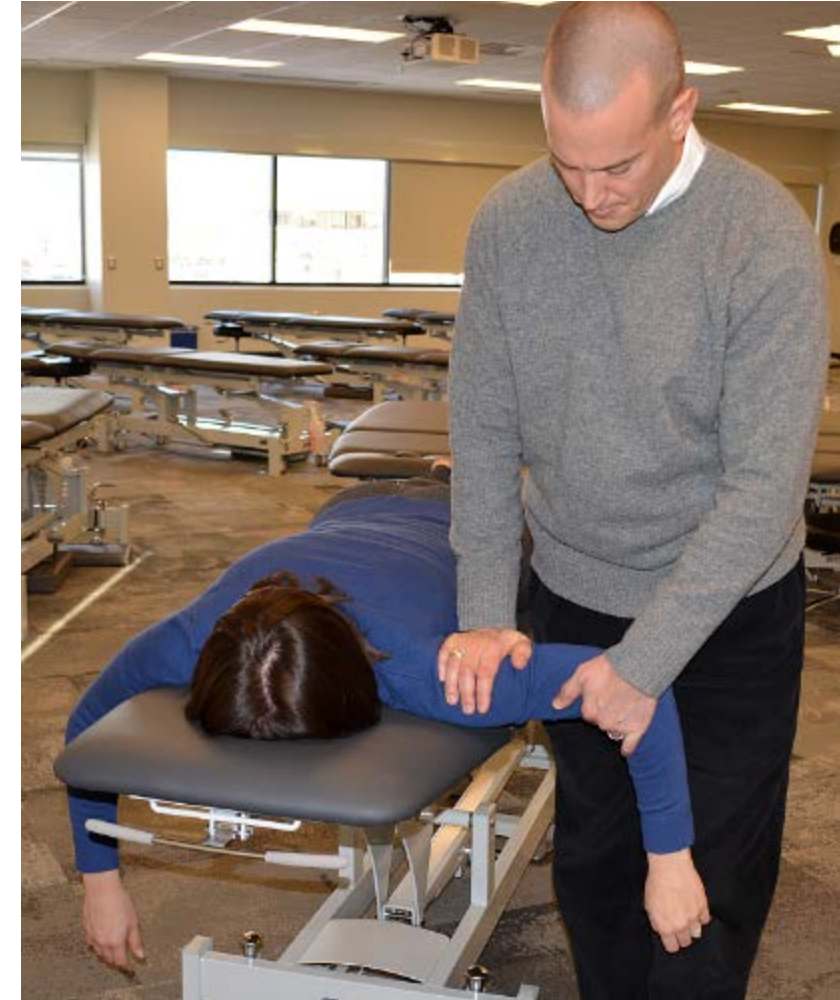## Treatment Order for UCS

Need to treat in the following sequence:

1. Release ligamentous capsule with arthrokinetic technique (if needed) - this allows the muscle to adapt it's length from a neuromuscular standpoint (via ME or SCS)
2. Muscle energy (or SCS – but usually ME due to chronicity) to bypass any neuromuscular tone issues & allow stretch
3. Passively stretch any hypertonic muscles to address any remaining muscle fiber or fascial restrictions.
4. Now you can retrain the inhibited muscle...

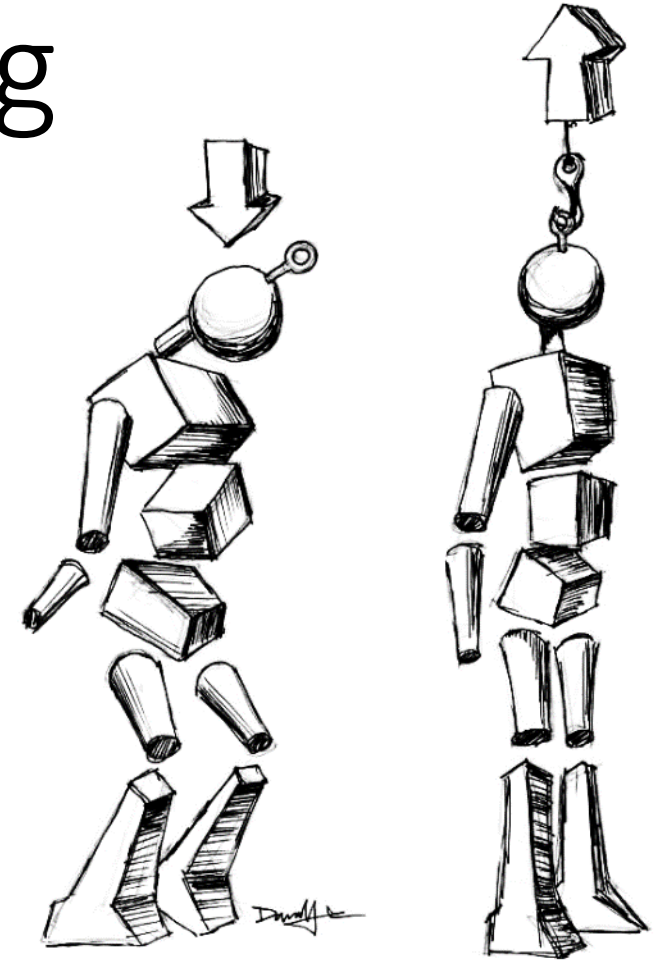
# UCS – Arthokinetic Tx

- W/ pt prone and medial hand posterior to the proximal humerus but off the scapula completely, horizontally abduct the shoulder until moderate resistance is encountered.
- With a moderate amount of force (10-20#), rhythmically apply a translatory force anteromedially through the glenohumeral joint without releasing initial tension point
- Abduct/adduct where resistance is met, & continue until loose.
- Recheck findings.



# Exercise Rx – Postural Retraining

- Imagine a cord coming up from the crown of your head (not the very top/middle of your head, but slightly toward the back directly over the foramen magnum). Imagine someone pulling that cord upward – your chin drops toward your Adam's apple & your spine elongates.
- Maintain the most upright of this posture as feels somewhat natural. Over weeks-months, your range of natural posture will move toward this ideal posture. Do NOT attempt to progress too quickly, you will make things worse!
- Use visual cues to remind yourself of this posture – use them anywhere you stand or sit for long periods of time (>10-15').





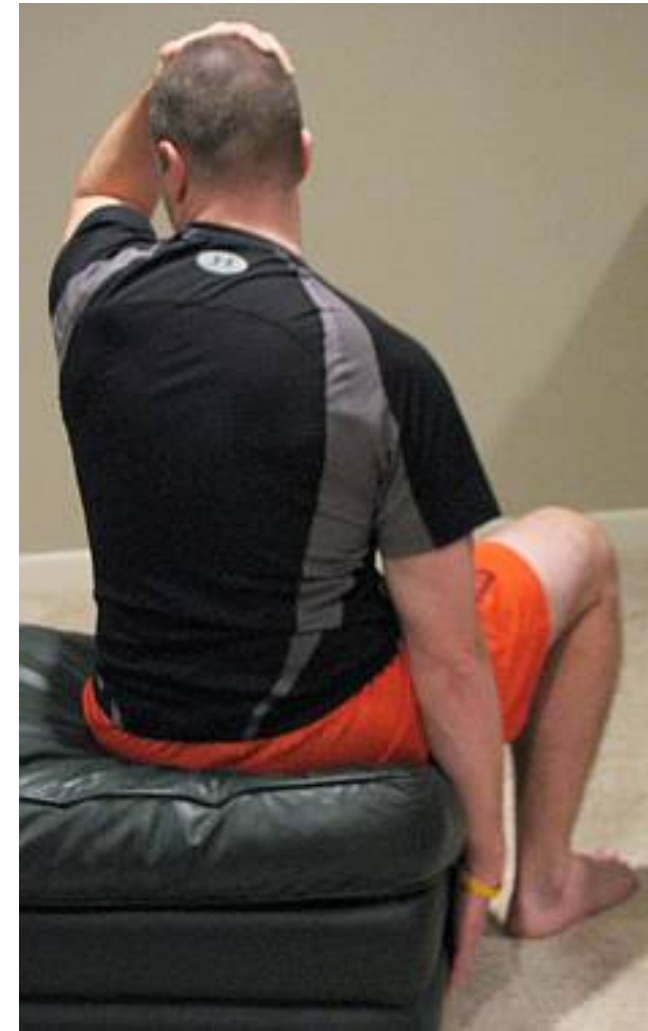## Exercise Rx For UCS – Pectoralis Stretch

- Standing w/ affected limb at approximately shoulder height, same side foot against wall.
- Gently contract scapula inferomedially toward T<sub>10</sub>
- W/ opposite hand holding body away from wall, slowly lean into the wall until early/mild stretch in calf is felt. If chest touches wall before stretch is felt, rotate trunk away from affected side & repeat.
- Hold for 10-15 secs then move to new barrier, or do other side and repeat.
- Can add adduction at shoulder toward wall to engage desired stretch. Can also raise or lower arm to augment stretch in desired portion of pectoralis.



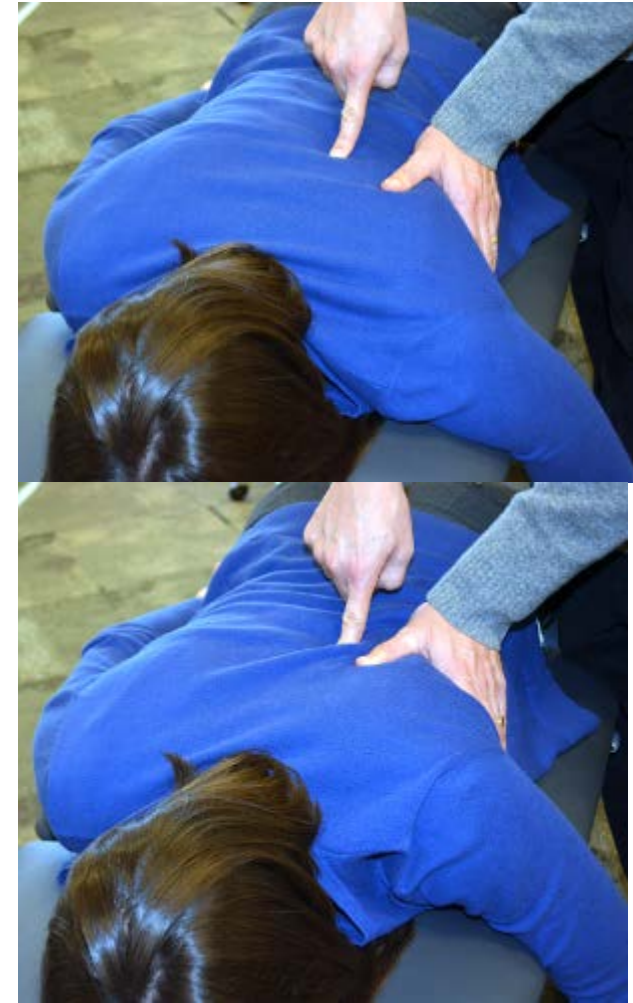## Exercise Rx For UCS – Lev. Scapula Stretch

- Seated w/ affected limb holding bottom of chair or rung below.
- W/ opposite hand holding head flexed, sidebent & rotated away same side hand until early/mild stretch in levator is felt.
- Hold for 10-15 secs then move to new barrier, or do other side and repeat.
- Can add sidebend/rotate/extend neck toward affected side to engage desired stretch.



## Exercise Rx For UCS – Lower Trap Retraining - I

- With pt prone & arm hanging off table, ask patient to draw/pull the scapula inferiorly and toward the spine, using lower trap and avoiding contraction of lat or upper trapezius.
- Pt might need monitoring of, or even pressure on, muscle to help locate the appropriate portion of the trap.
- Hold for 5-7 seconds, then slowly let scapula return by releasing lower trap steadily. Rest for 4 seconds.
- Repeat as often as you can to perform a good, **isolated** contraction, up to 10.
- Then move on to Phase II training.



## Exercise Rx For UCS – Lower Trap Retraining - II

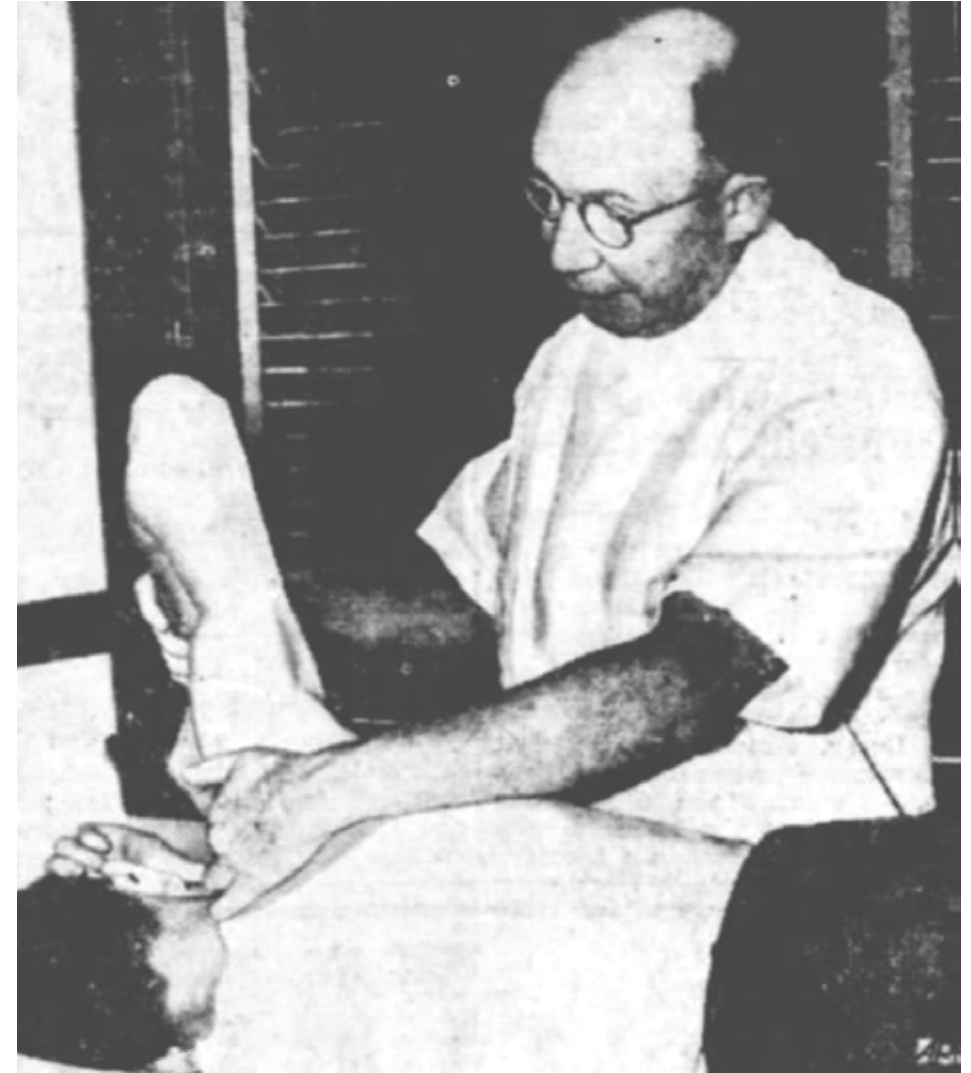
- Pt seated & forming a triangle with both thumbs and forefingers, ask patient to draw/pull the scapula & arms toward the spine, using lower trap and avoiding contraction of lat or upper trapezius.
- Hold for 5-7 seconds, then slowly return to starting position. Rest for 4 seconds.
- Repeat as often as you can to perform a good, **isolated** contraction, up to 10.
- Then move on to more standard lower trap and rhomboid strengthening (e.g., rows).



# Glenohumeral Joint

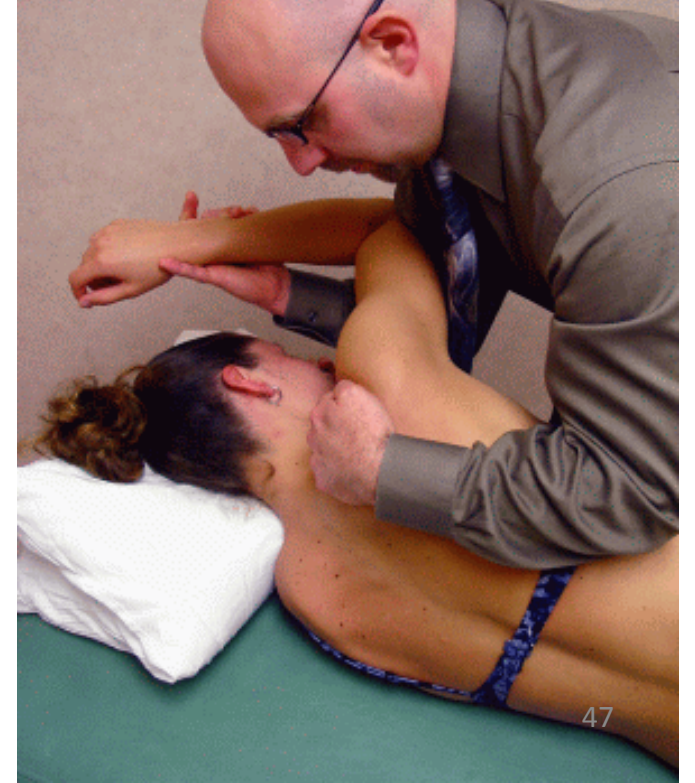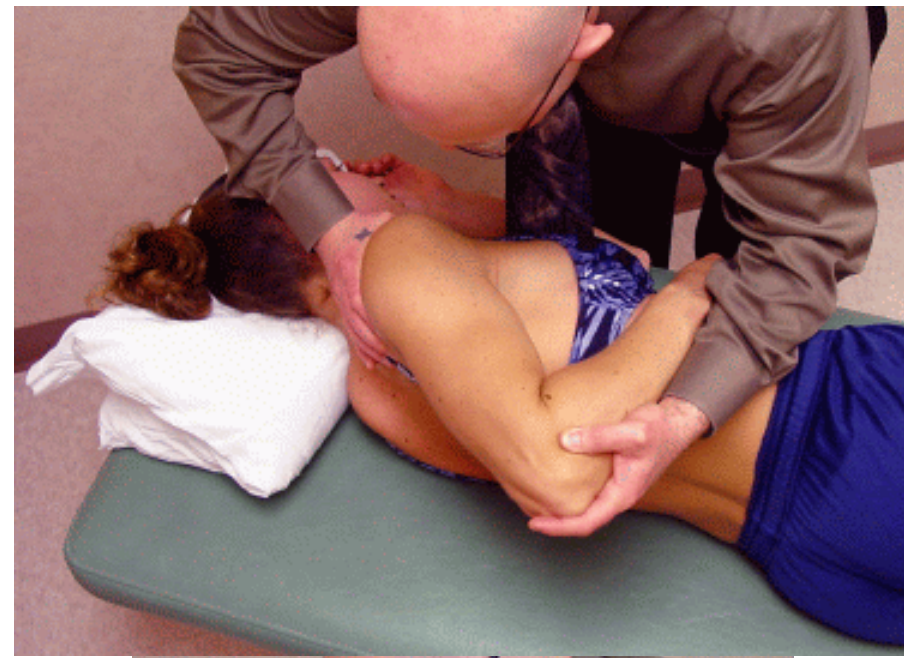# Spencer Technique

- A classically described shoulder technique, originally used on baseball pitchers.
- This is a modification adding a muscle energy component that is very effective.
- Seven steps engaging motion around three axes, and along one axis, engaging all of the major muscles around the glenohumeral joint.
- Properly done, very gentle and welltolerated.



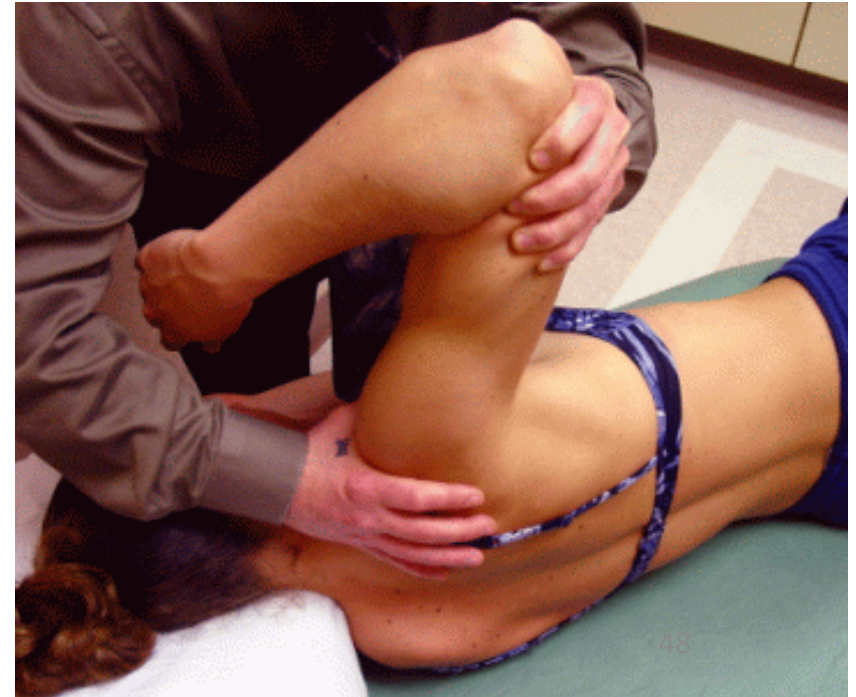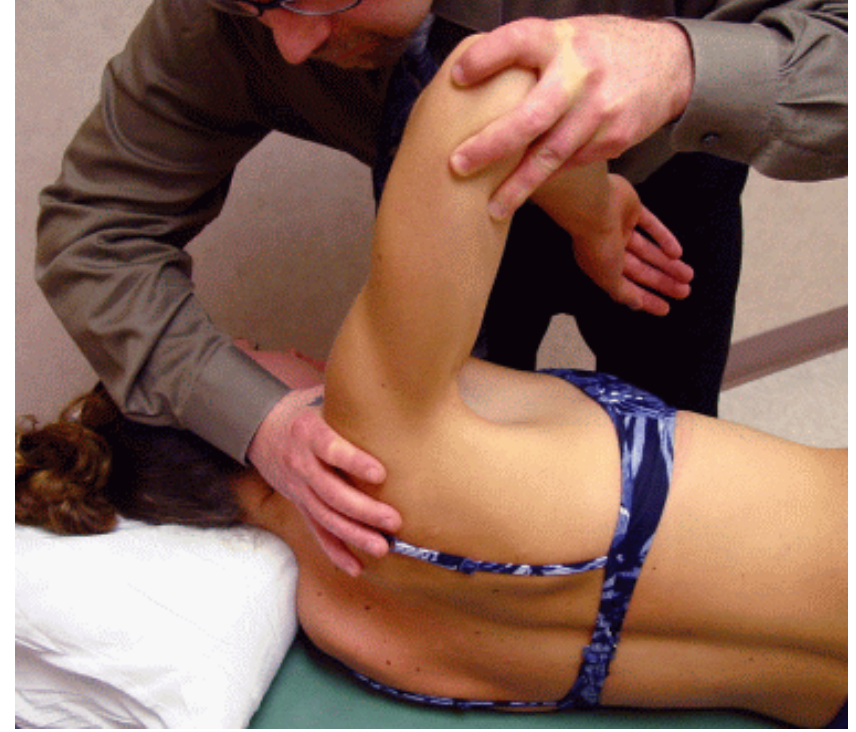# Spencer #s 1 & 2: Extension & Flexion

- Stabilize the scapula and clavicle with one hand.
- Engage the barrier to extension and ask patient to flex the arm while operator resists motion.
- Repeat 3-5 times, taking up slack and engaging new barrier after each repetition.
- Repeat this pattern engaging flexion barrier.



# Spencer #s 3 & 4: Internal & External rotation

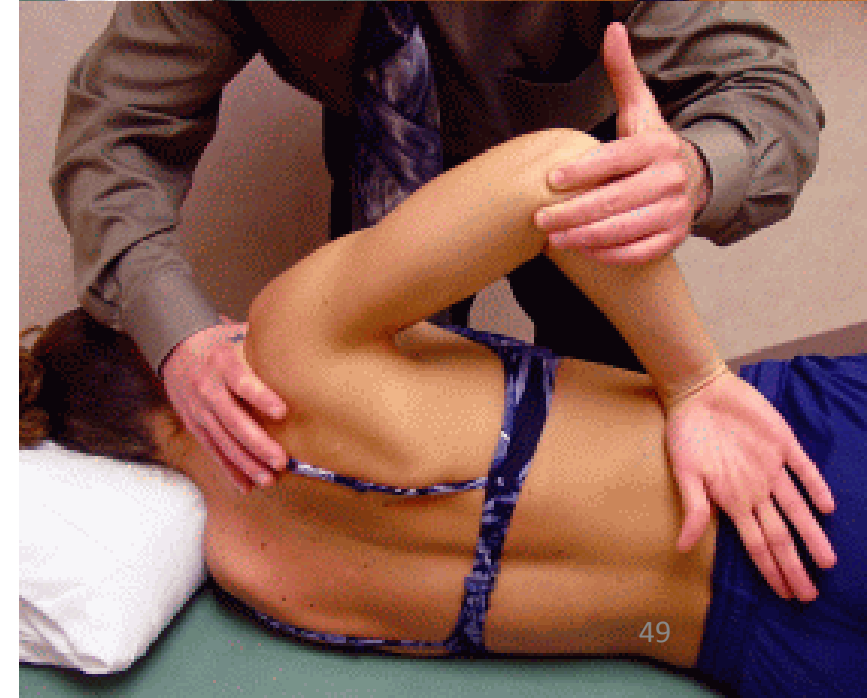- Stabilize scapula & clavicle with one hand.
- Engage the barrier to internal rotation and ask patient to externally rotate while the operator resists the motion
- Repeat 3-5 times, taking up slack & engaging new barrier after each rep.
- Repeat this pattern engaging external rotation barrier.





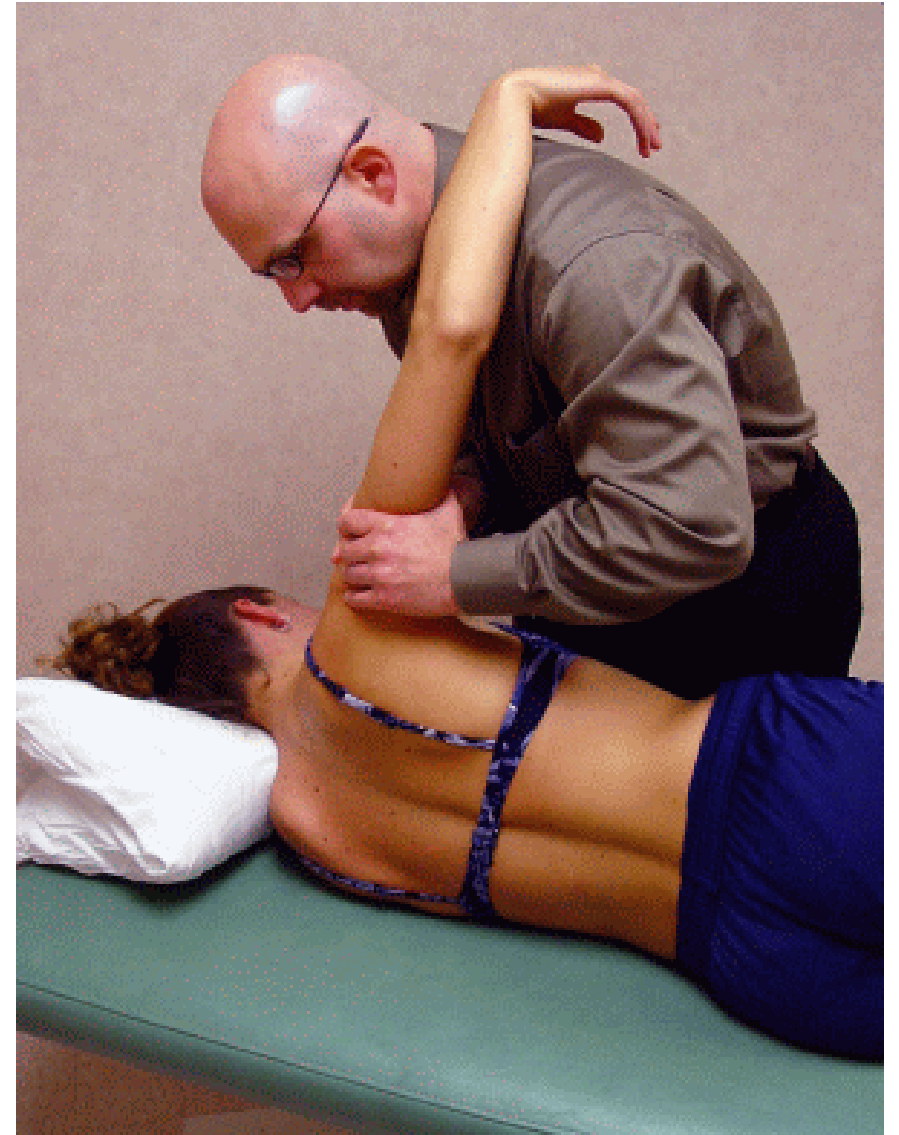
# Spencer #s 5 & 6: Abduction / Adduction

- Stabilize the scapula & clavicle w/ one hand.
- Patient's hand is placed on operator's forearm. Barrier to adduction is engaged, patient asked to abduct, while operator resists motion.
- Repeat 3-5 times, taking up slack and engaging new barrier after each repetition.
- Repeat this pattern engaging abduction rotation barrier.
- Notice that this is not true abduction/adduction, but all of the shoulder motions have now been engaged.



# Spencer Step 7: Glenohumeral Pump

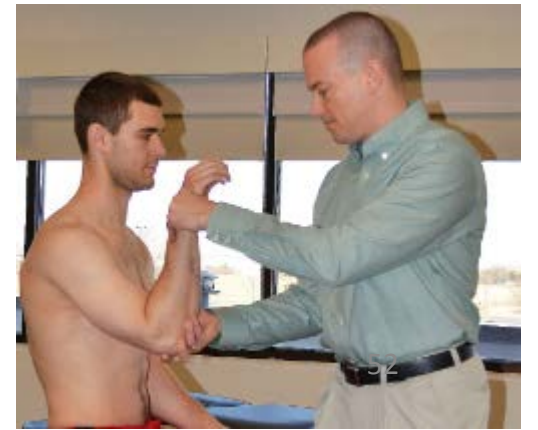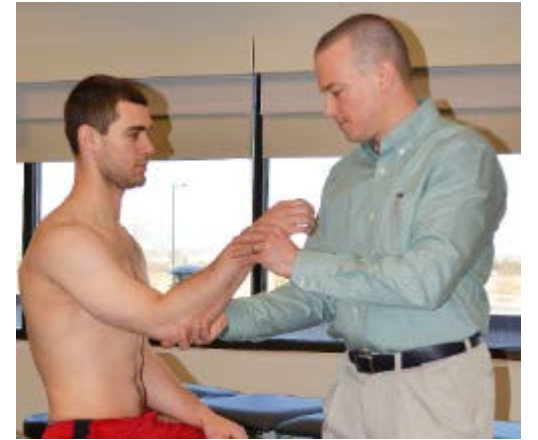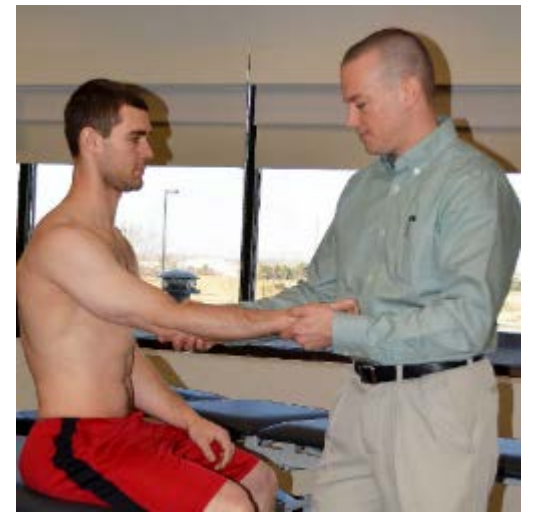- Grasp humeral head w/ fingers around the greater tuberosity & thumbs in the axilla.
- Gentle distraction & compression is applied along the axis of humerus into glenoid.
- Repeat 3-5 times.



# Radial Head

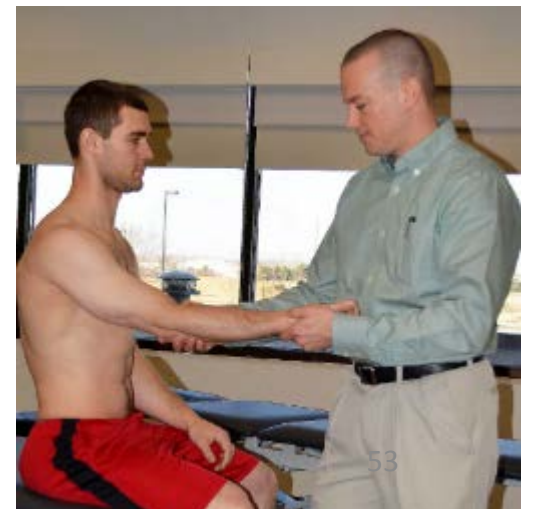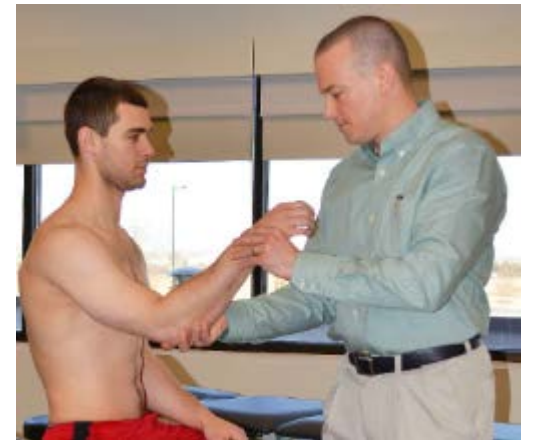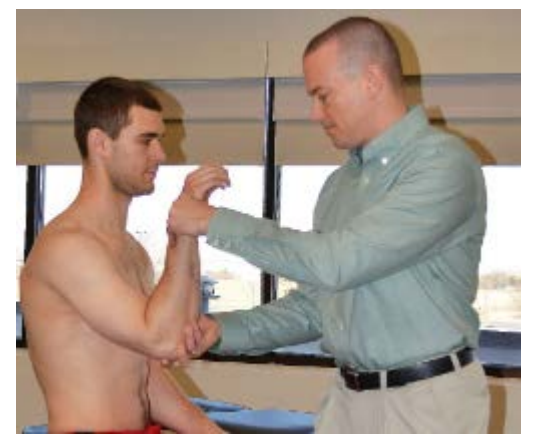
# Still Technique – Ant. Radial Head

- Start in an indirect fashion (supinated, with the elbow extended) and add *gentle* (perhaps 0.5 kg) pressure toward the radial head
- Slowly move the arm toward the barrier (fully pronated, with the elbow flexed) as you maintain the gentle tension/pressure throughout the range
- Recheck



# Still Technique – Post. Radial Head

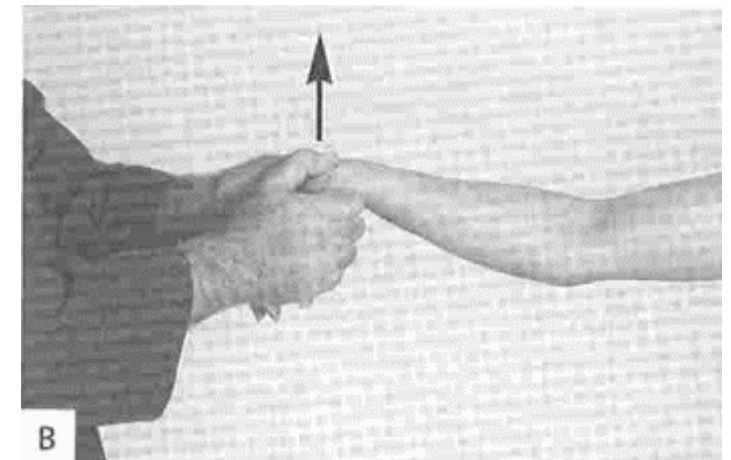
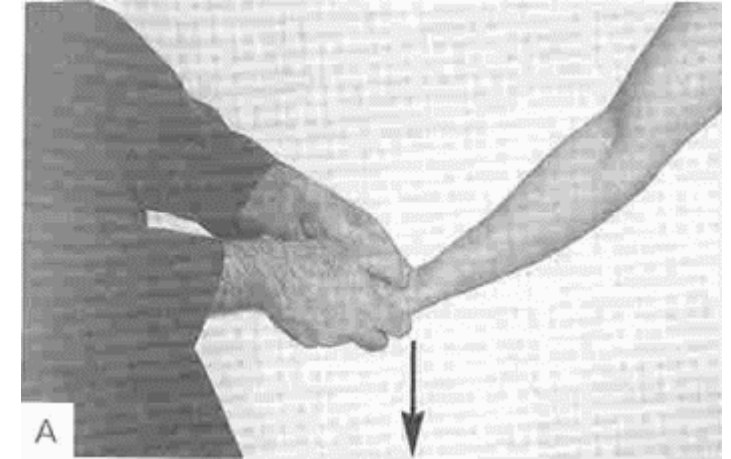
- Start in an indirect fashion (pronated, with the elbow flexed) and add *gentle* (perhaps 1#) pressure toward the radial head
- Slowly move the arm toward the barrier (fully supinated, with the elbow extended) as you maintain the gentle tension/pressure throughout the range
- Recheck



# Wrist & Hand

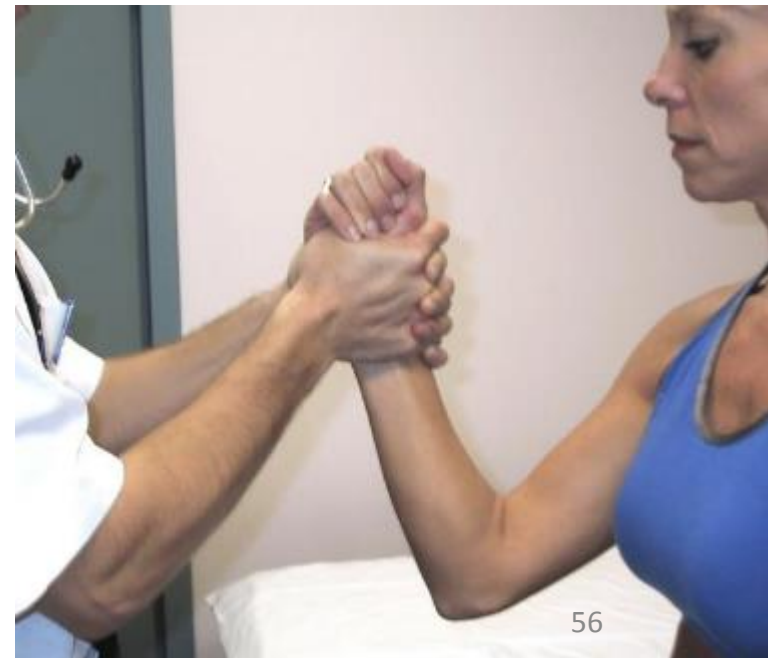
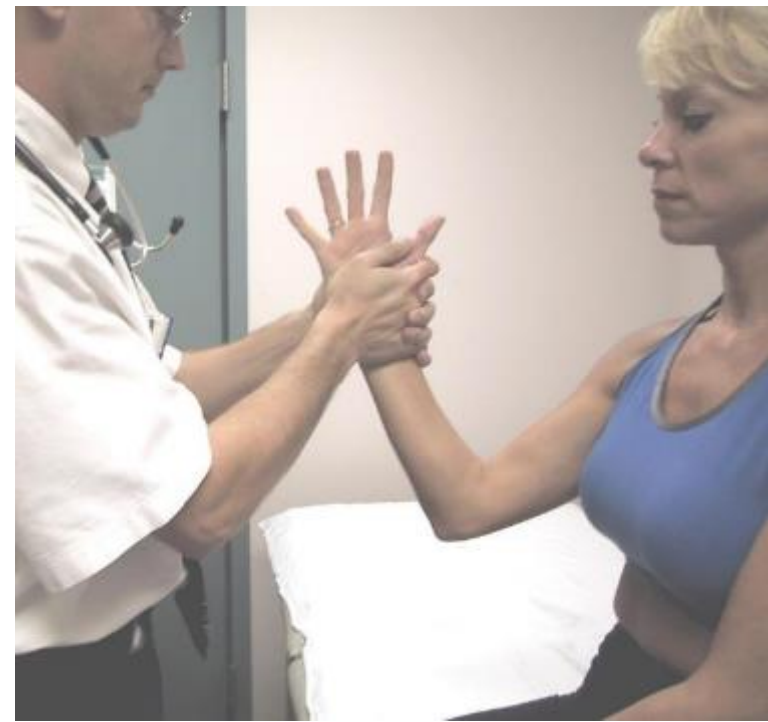## Carpal Mobilization

- General mobilization technique for wrist joint (radio/ulnocarpal)
  - Proximal row
  - Distal row
- Circumduction of the carpals



# Decompress the Carpal Tunnel

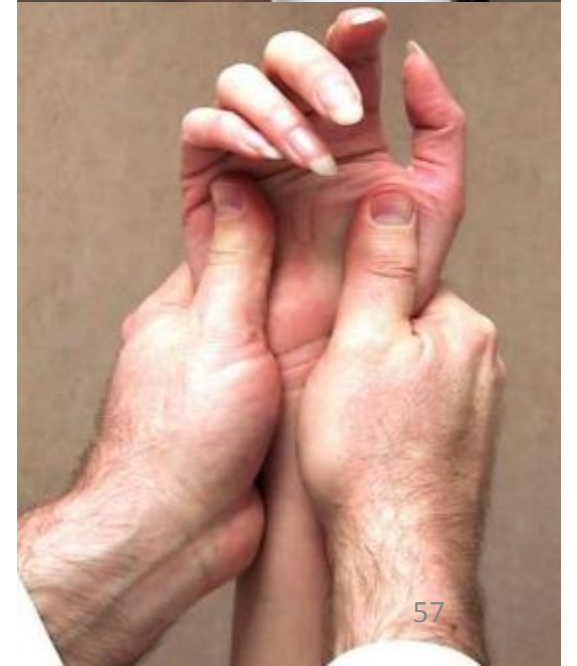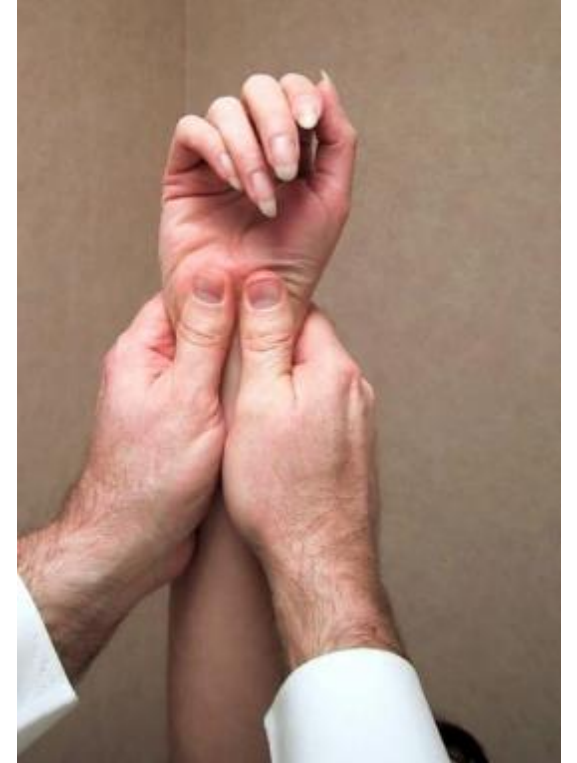
- Pump technique
  - Compress carpal tunnel firmly (but not to the point of strangulation!) between physician's palms, fingers interlaced if possible
  - Pt actively and fully flexes and extends fingers while physician maintains compression for several cycles
  - Pt may notice temporary flare of symptoms during and very shortly after treatment, but has a long-term benefit overall.





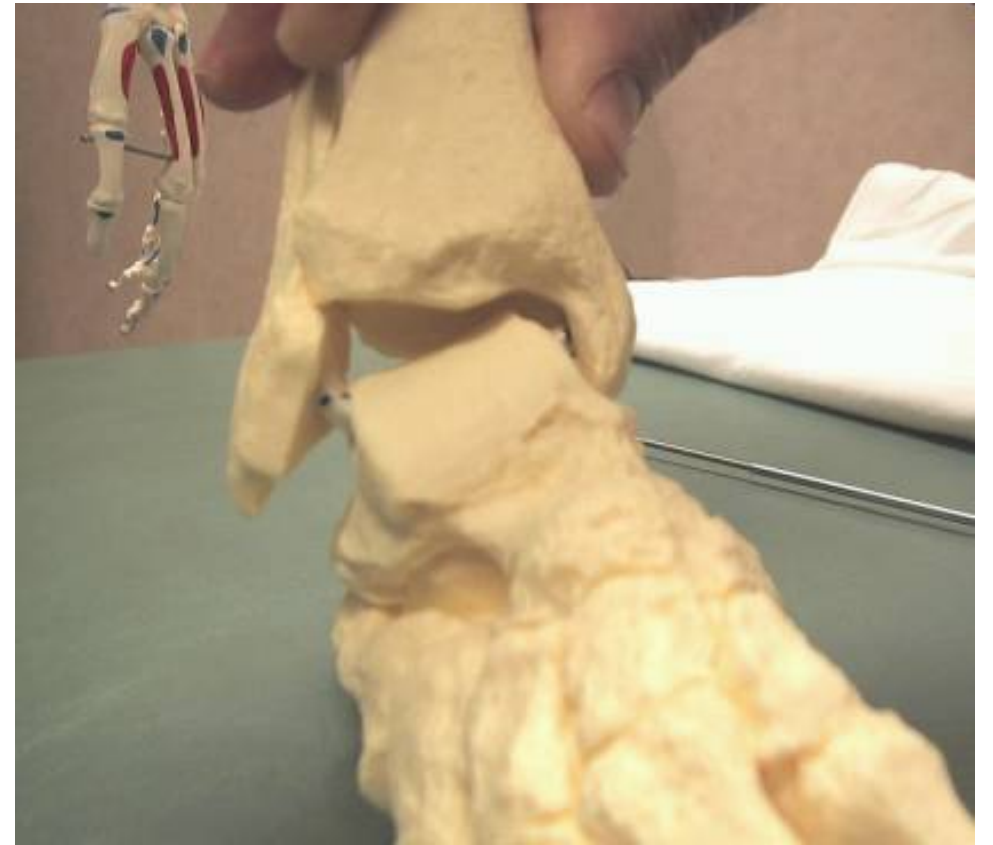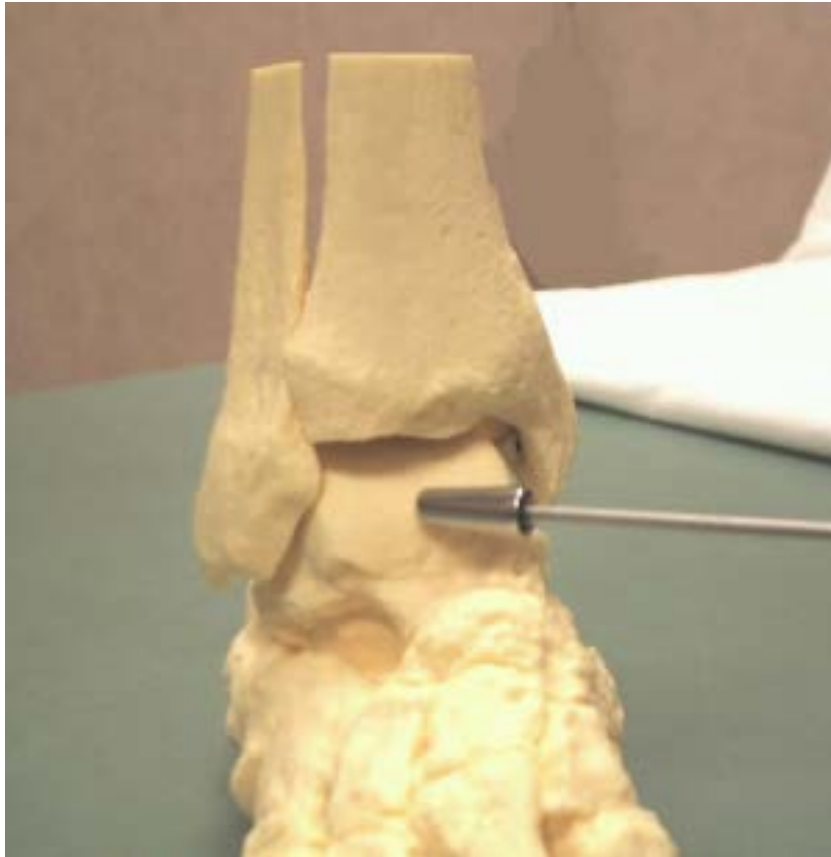
# The Wrist & Hand

- Lymphatic Drainage
  - Physician begins with pt's arm extended in a relaxed fashion toward ceiling, allowing for gravity to assist with drainage
  - Starting with thumbs approximated at distal carpal tunnel, physician spreads thumbs along the palmar fascia up to the MCP joints (as if "fanning" a hand of cards)
  - Perform several cycles of this



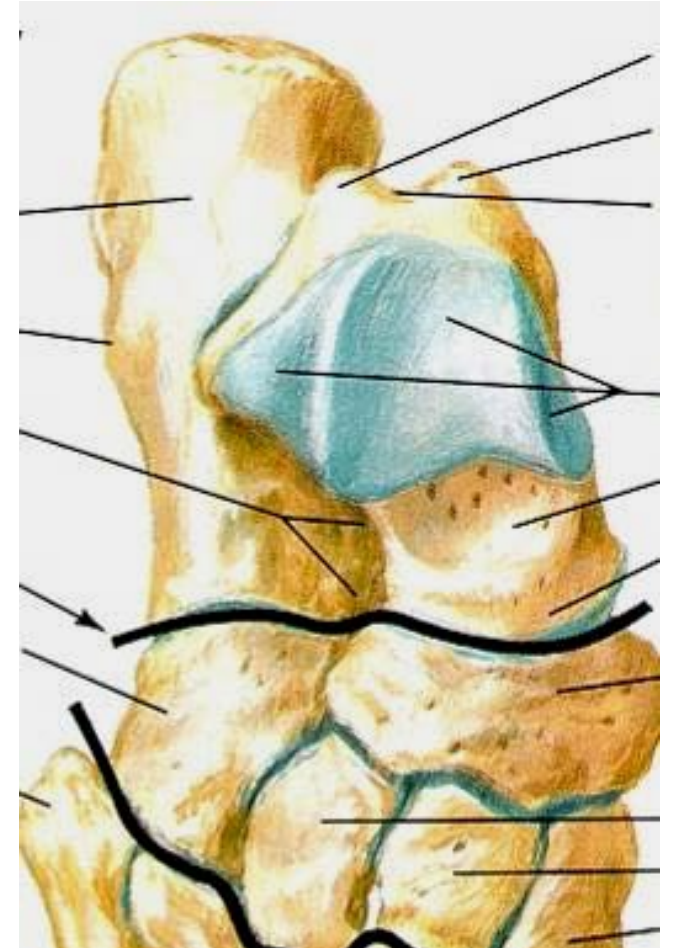
# Lower Extremity

# Inversion Ankle Sprain



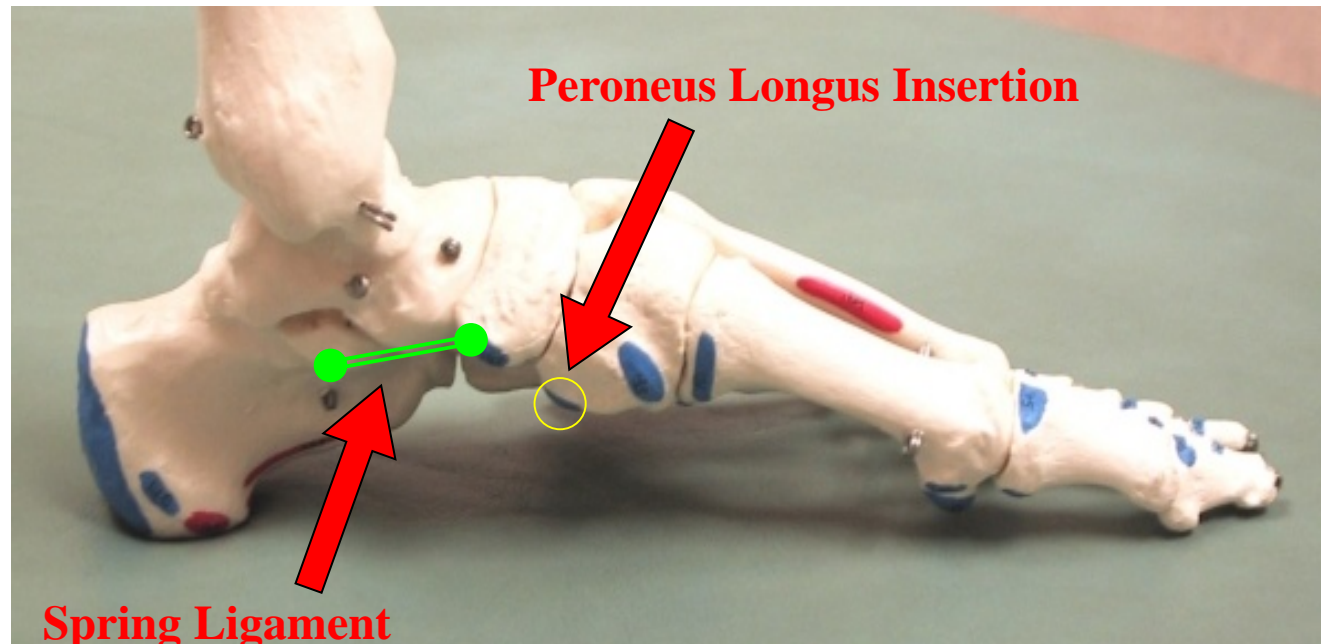
# Inversion Ankle Sprain

- Typically with plantar flexion
  - Thin posterior portion of talus offers little ankle stability, relying primarily on soft tissue support
- Peroneal muscles eccentrically loaded rapidly
- Weight of body coming down ‘jams’ talus into the crural (distal tib/fib) articulation



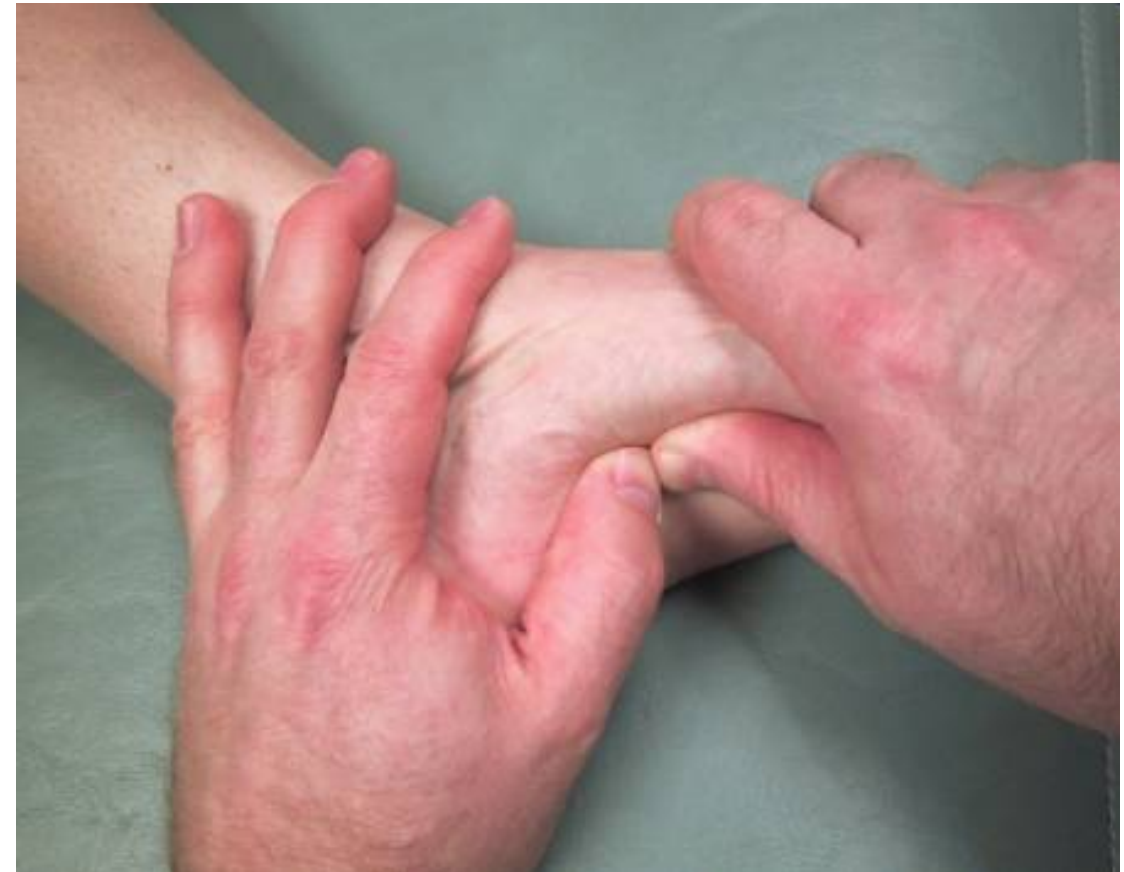# Navicular Dysfunction

- Peroneus longus tendon inserts on medial cuneiform bone - with inversion, it pulls inferiorly & “collapses” the arch via the navicular-cuneiform ligament
- Can be acute or chronic
- Can also occur due to dysfunction elsewhere (hamstrings, sacrum, etc.)



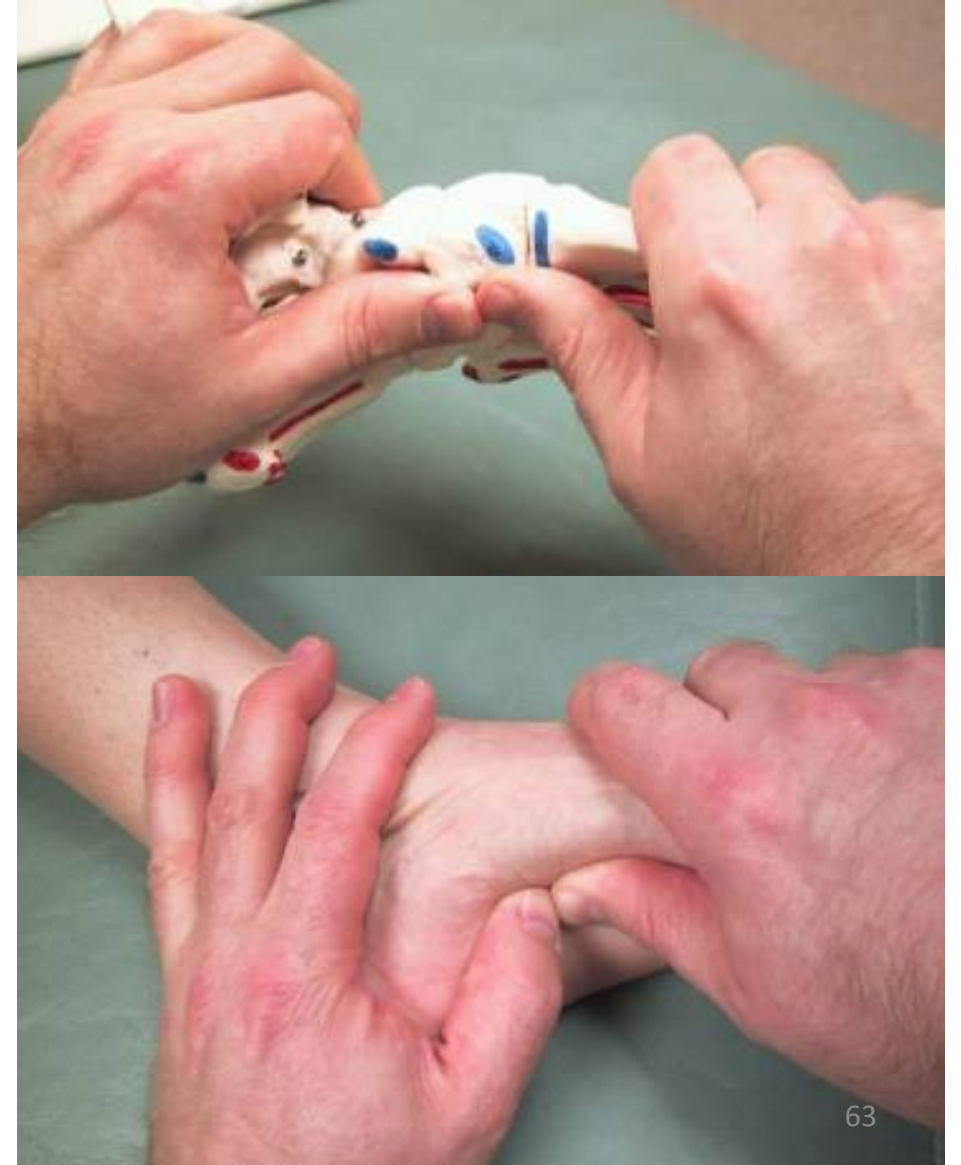
# Navicular Dysfunction

- Palpation of arch reveals a more prominent (& usually tender) navicular bone in arch medially
- Pronation may be noticeable in standing examination



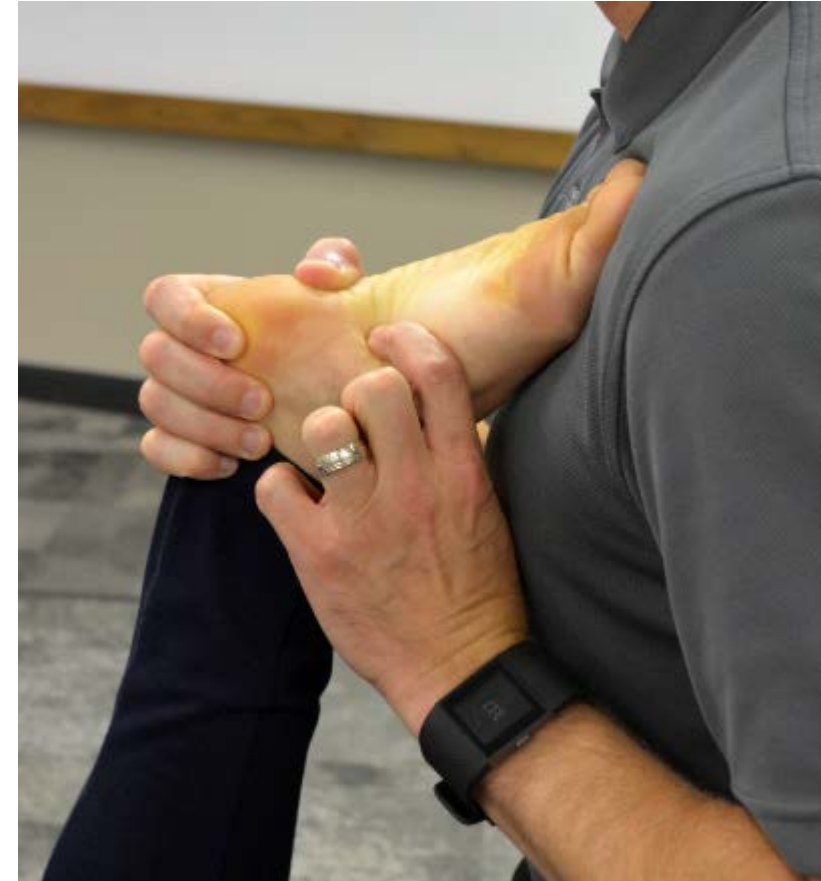# Navicular Dysfunction - Articular

- Restore arch by gapping superior aspects of navicular & cuneiform bones & applying plantar → dorsal pressure
  - Can be done with one rapid action (more of HVLA) or with slow steady pressure
- Recheck findings



# Navicular Dysfunction - SCS

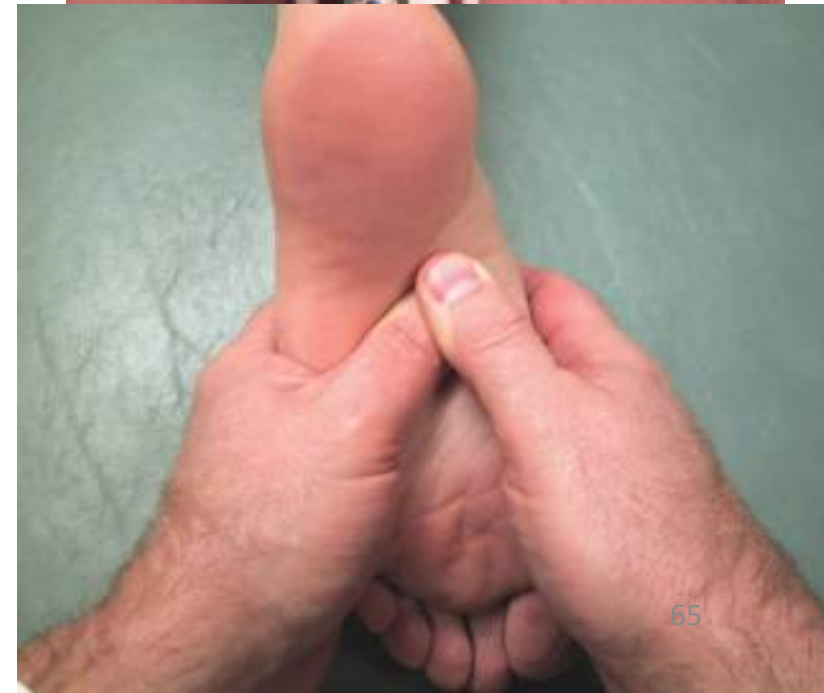
- Find most tender point in tissues over navicular
- With pt prone, greatly flex forefoot & invert/evert forefoot until tender point 70% (& can go for more) gone
- Maintain position with pt stabilized passively for 90 seconds
- Return (passively) to neutral
- Recheck findings



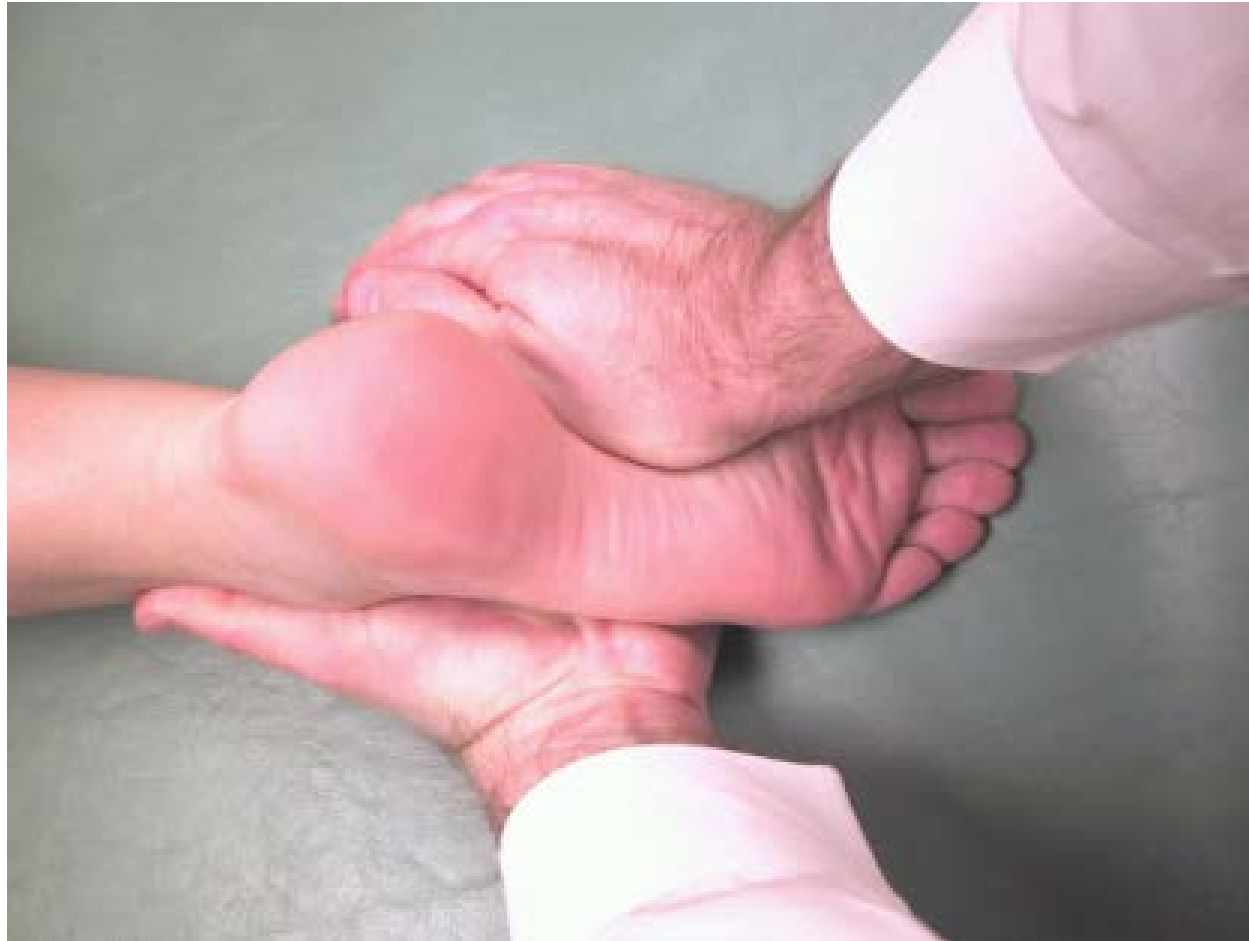

# Navicular “Whip”

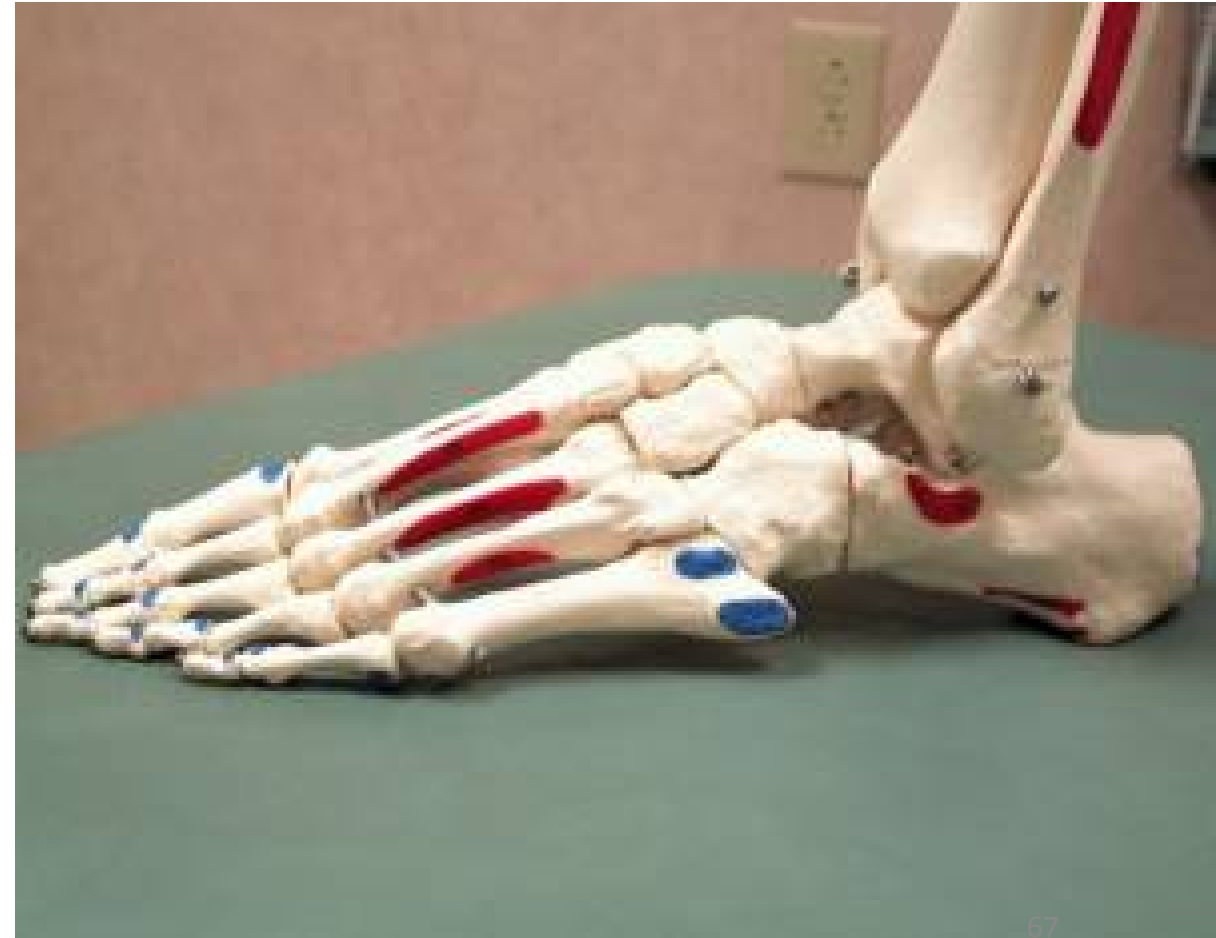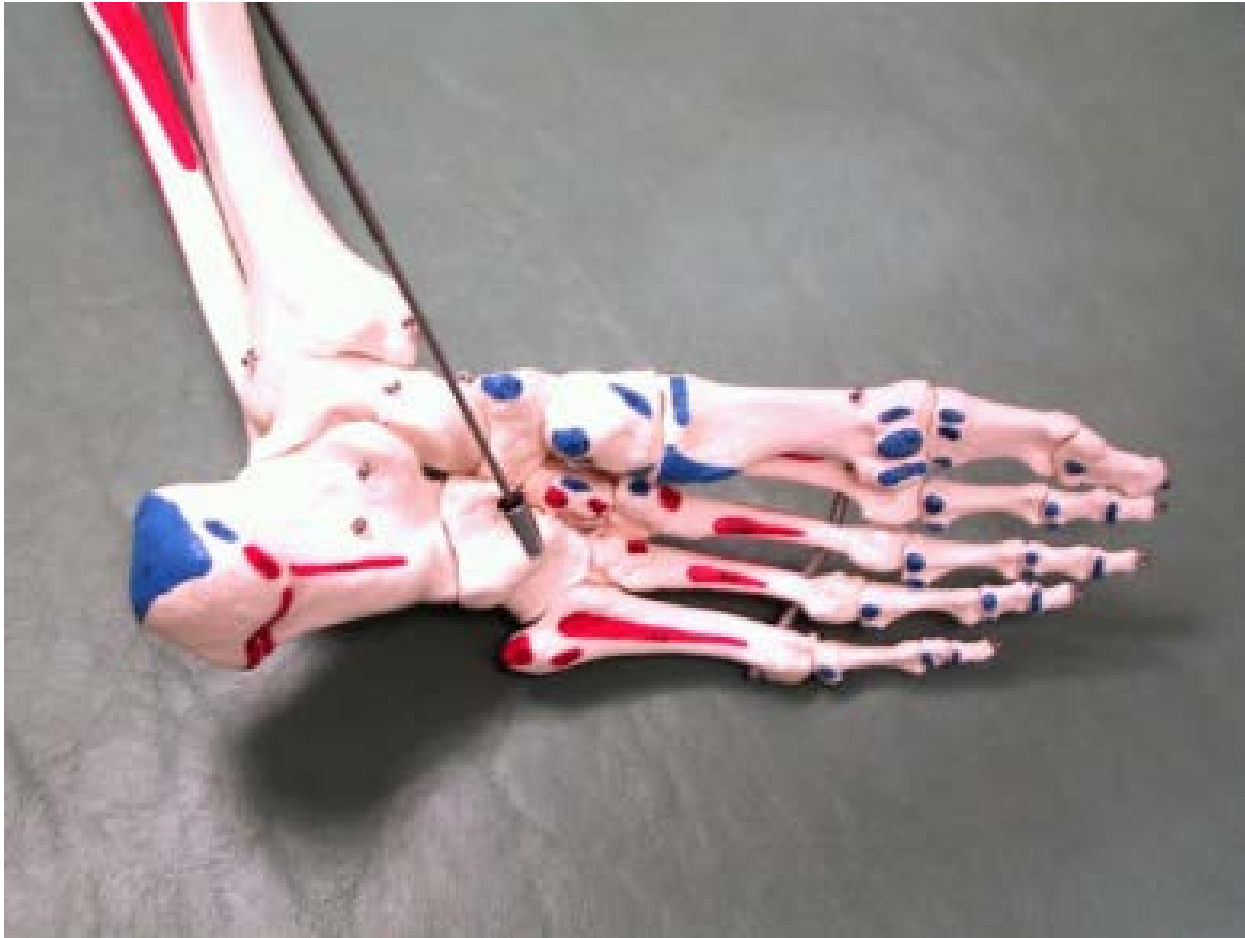
- With patient prone & leg relaxed, place thumbs over plantar aspect of navicular bone
- While plantar flexing the foot, apply a **valgus** motion to the ankle as you ‘snap’ or ‘whip’ the navicular bone dorsally
- Recheck your findings



# Navicular Dysfunction – “Molding”

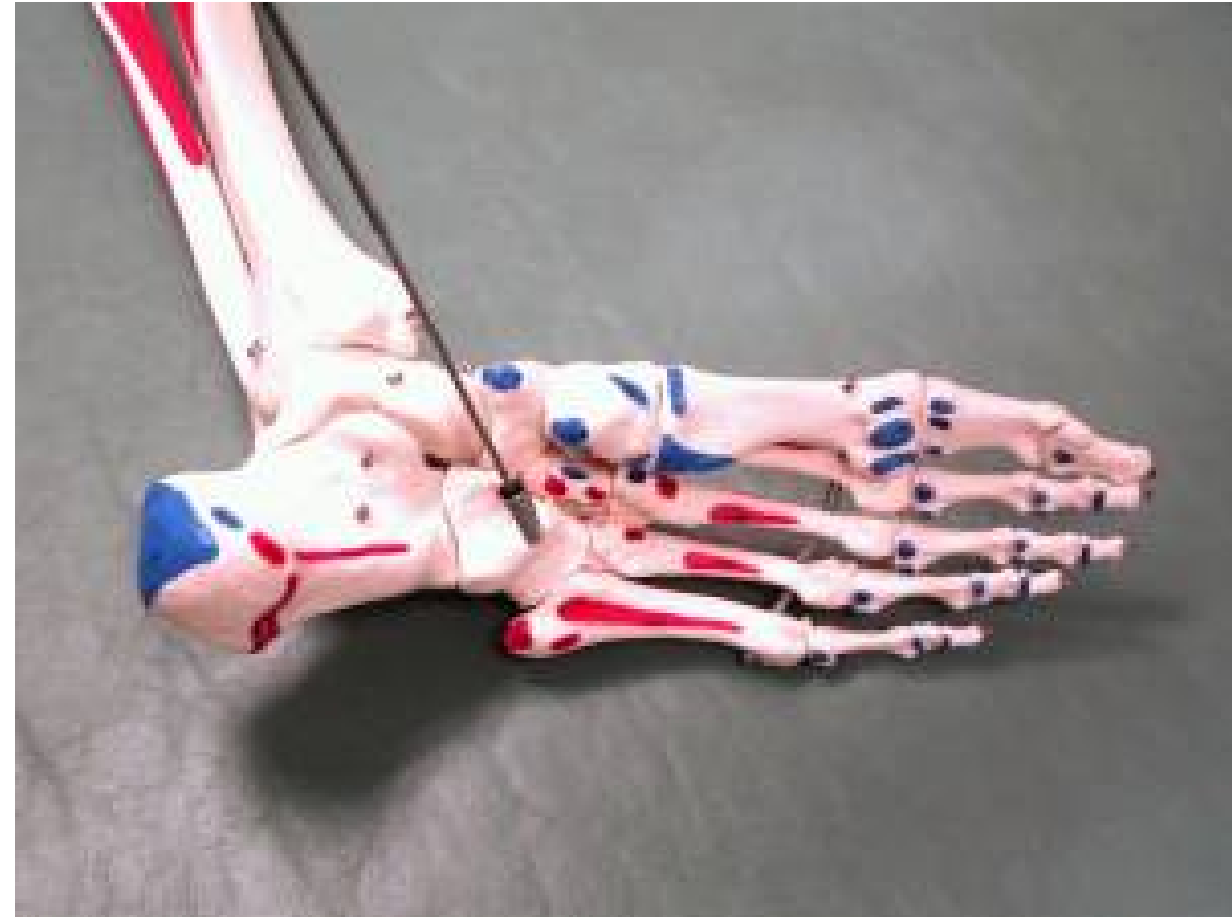


# Cuboid Dysfunction



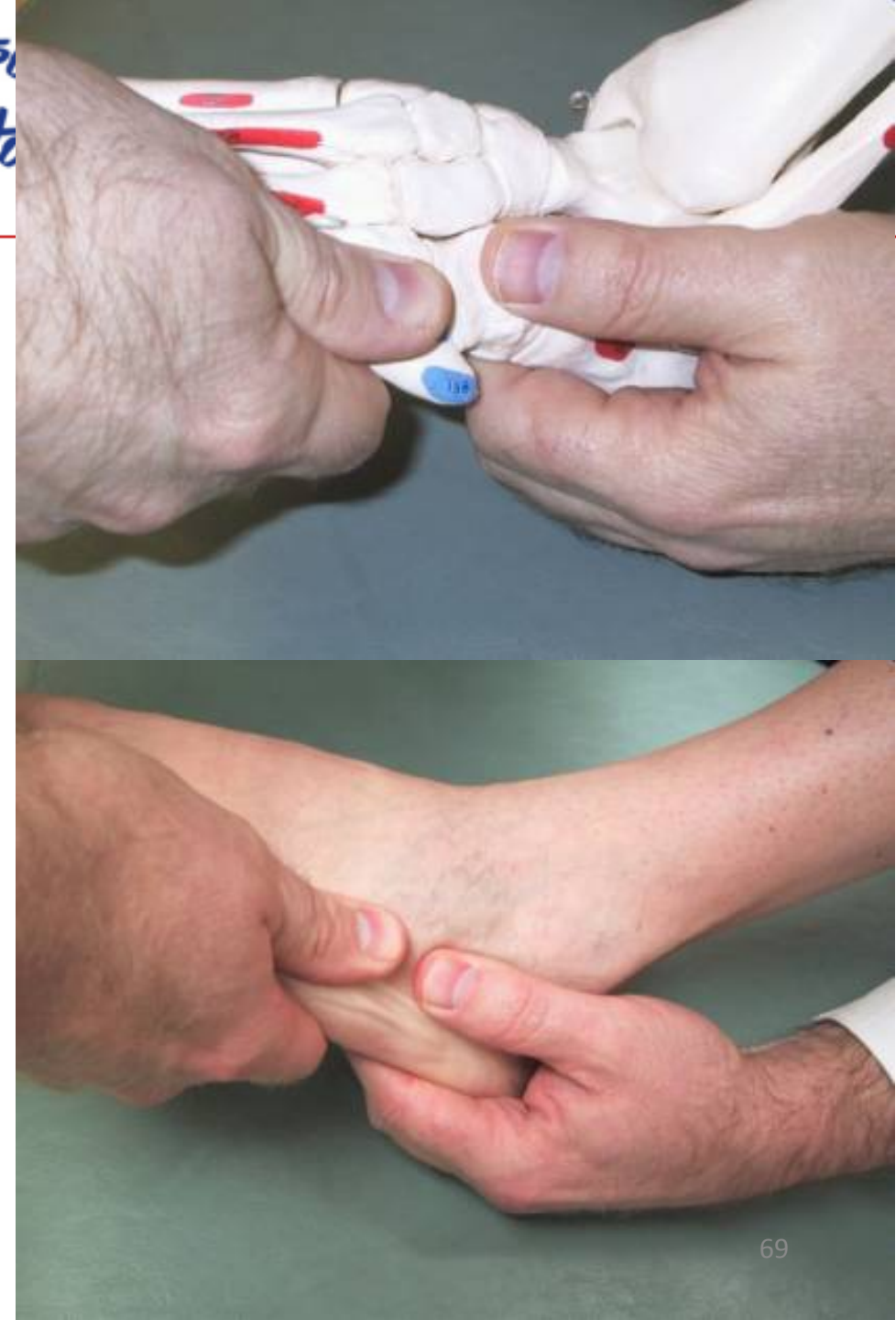
# Cuboid Dysfunction

- Palpation of arch reveals a more prominent (& usually tender) cuboid bone in arch laterally
- Pronation may be noticeable in standing examination, but due to guarding, patient may exhibit supination



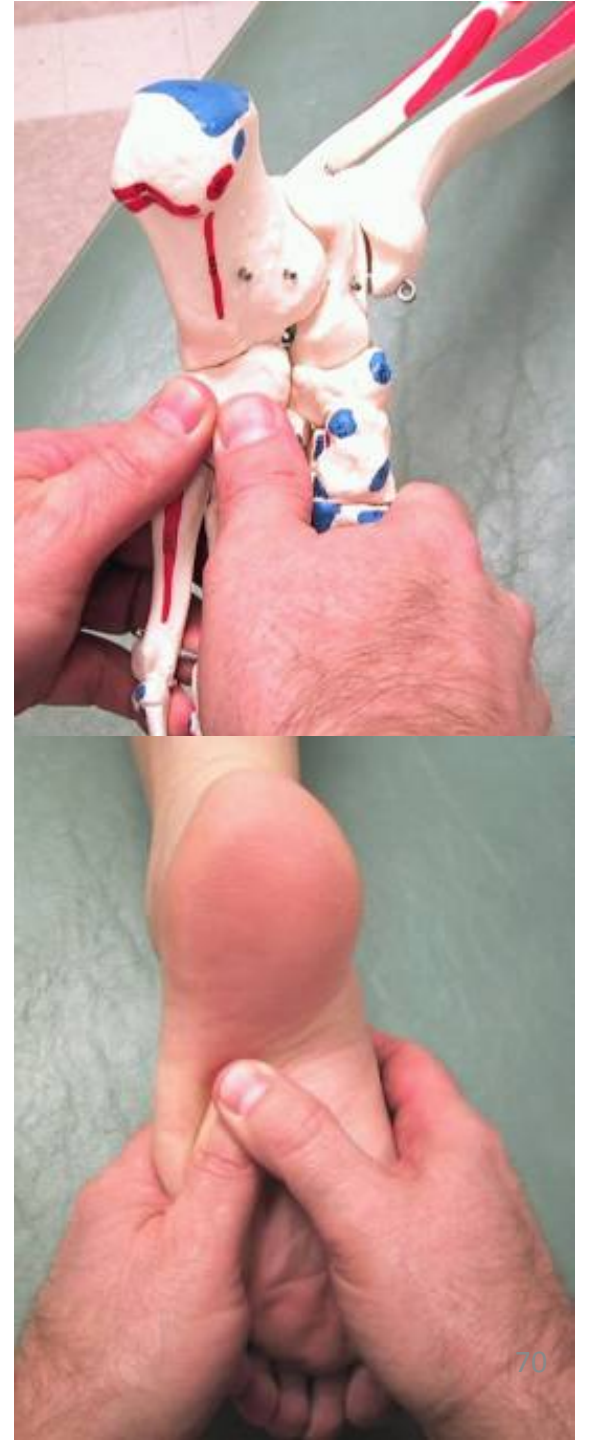# Cuboid Dysfunction – Articular / LVHA

- Can be treated in a mirror fashion as navicular, but also may be addressed by grasping cuboid snugly & ‘chalking’ the 5<sup>th</sup> metatarsal head onto the cuboid gently, or the cuboid onto the calcaneus.



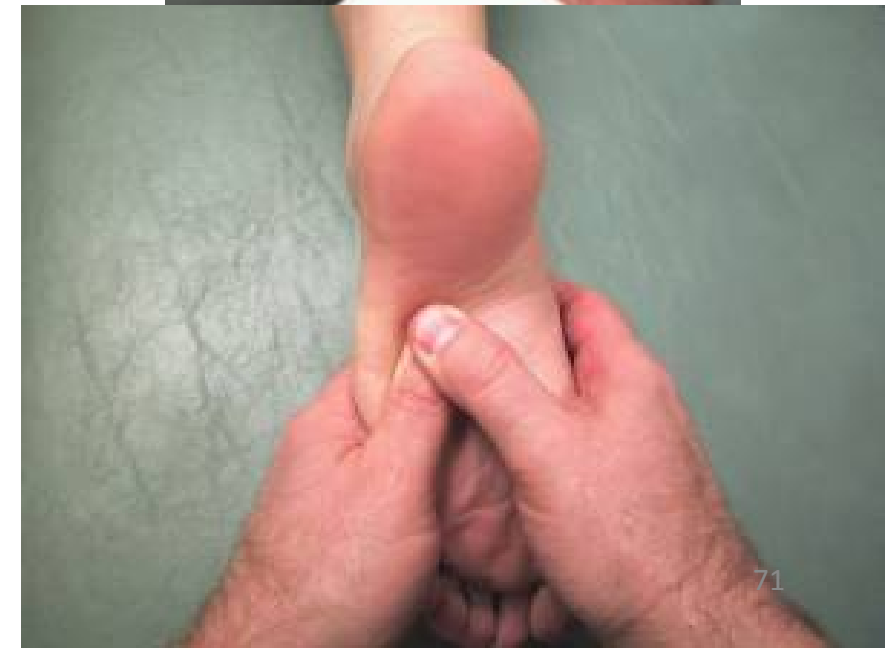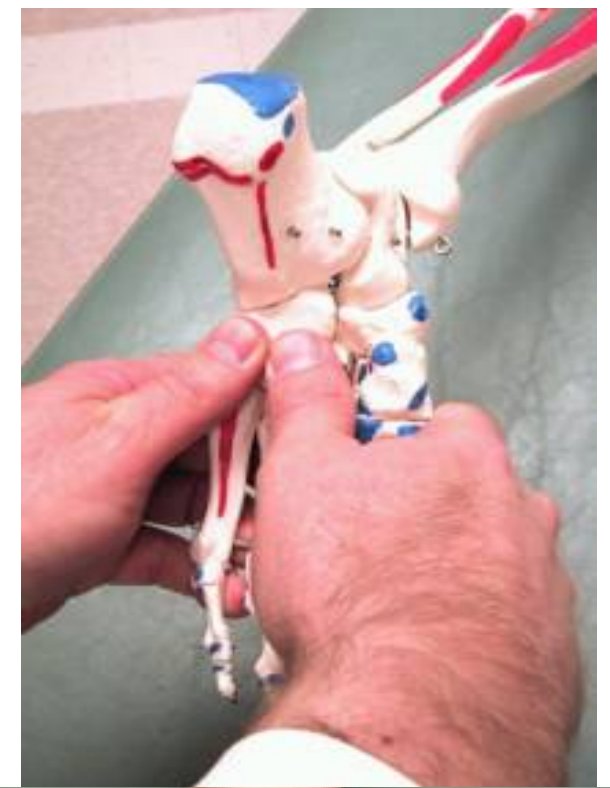
# Cuboid Dysfunction - SCS

- Can also be treated successfully with strain-counterstrain
  - Find most tender point in tissues over cuboid
  - With pt prone, greatly flex forefoot & invert/evert forefoot until tender point 70% (& can go for more) gone
  - Maintain position with pt stabilized passively for 90 seconds
  - Return (passively) to neutral
- Recheck findings

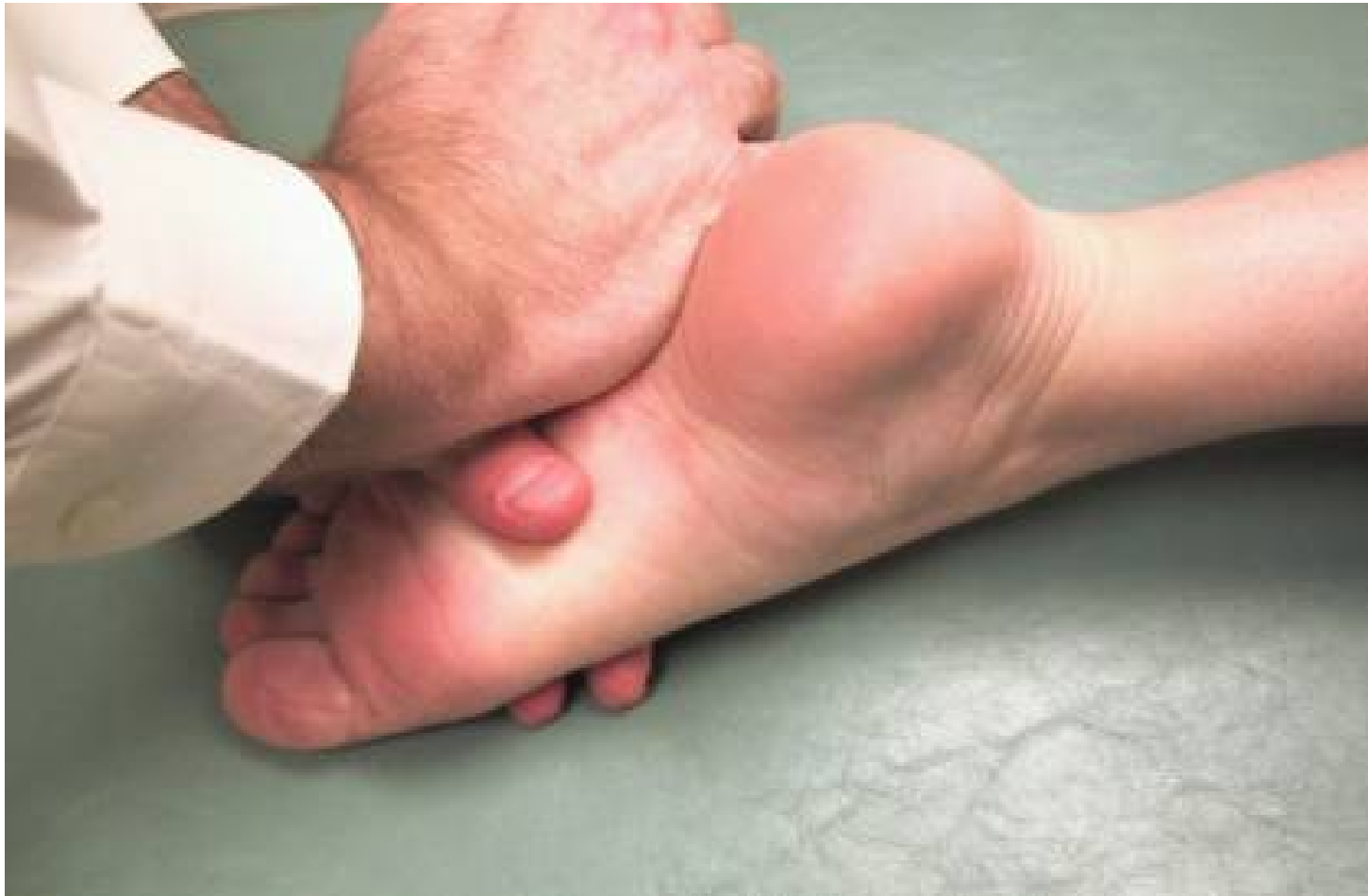

# Cuboid “Whip” - HVLA

- With patient prone & leg relaxed, place thumbs over plantar aspect of cuboid bone
- While plantar flexing the foot, apply a varus motion to the ankle as you ‘snap’ or ‘whip’ the cuboid dorsally
- Recheck your findings



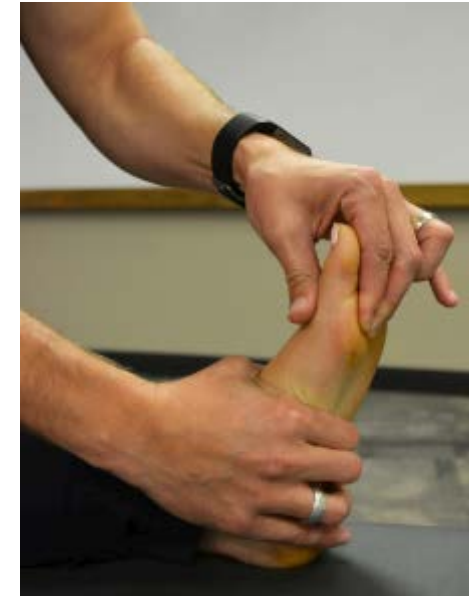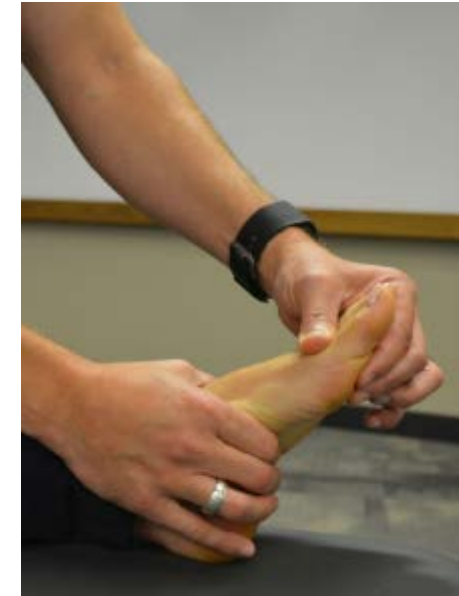# Cuboid Dysfunction – “Molding”





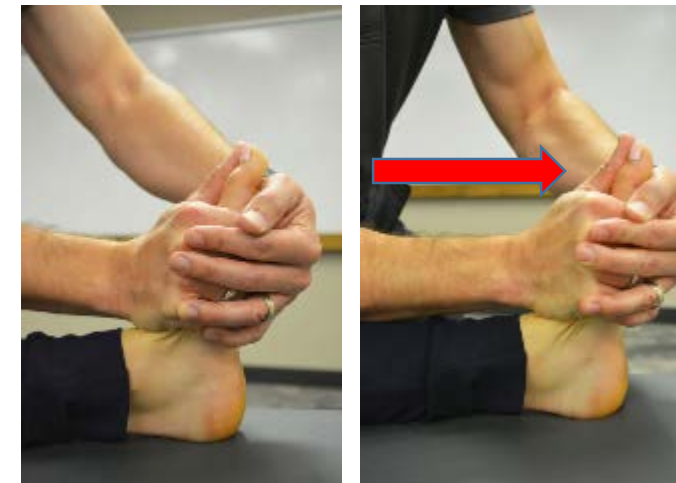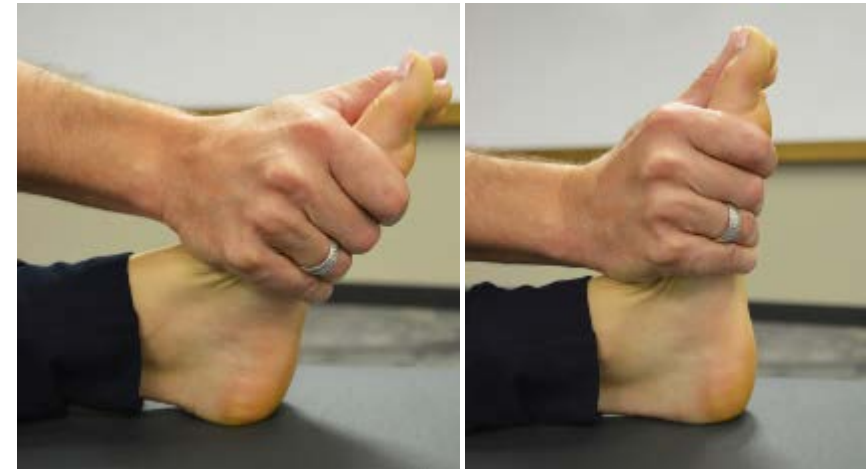## HVLA for plantarflexed 1<sup>st</sup> TMT Dysfunction - Dx

- With the 1<sup>st</sup> cuneiform stabilized, dorsiflex and plantarflex the 1<sup>st</sup> TMT joint via the distal MT head
- Will find restricted dorsal motion at 1<sup>st</sup> MT head (compared to opposite side) and end-feel will be rigid/articular in nature



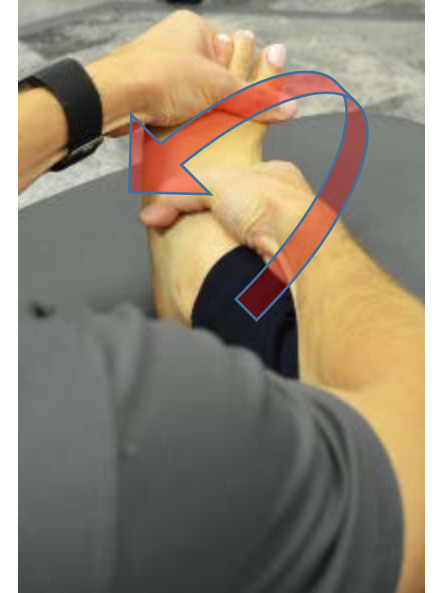
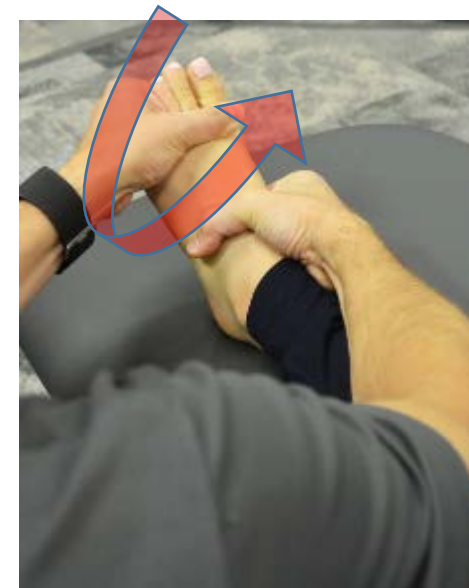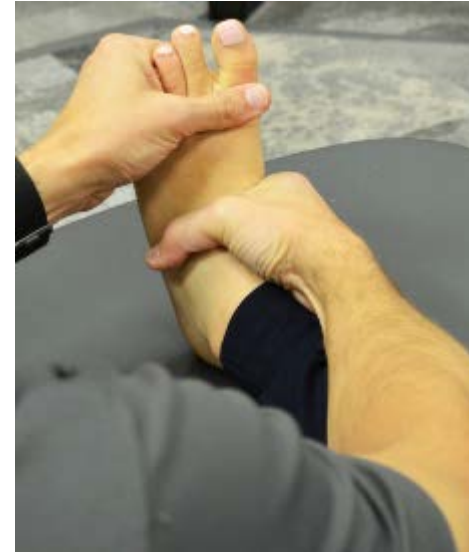## HVLA for plantarflexed 1<sup>st</sup> TMT Dysfunction - Tx

- Dorsiflex the foot, using the TMT joint as a fulcrum.
- Use of other hand is optional, but recommended.
- With a straight traction force, drive the hypothenar eminence of the dorsal hand distally along the plane of the tibia.
- Recheck, regardless of audible response...



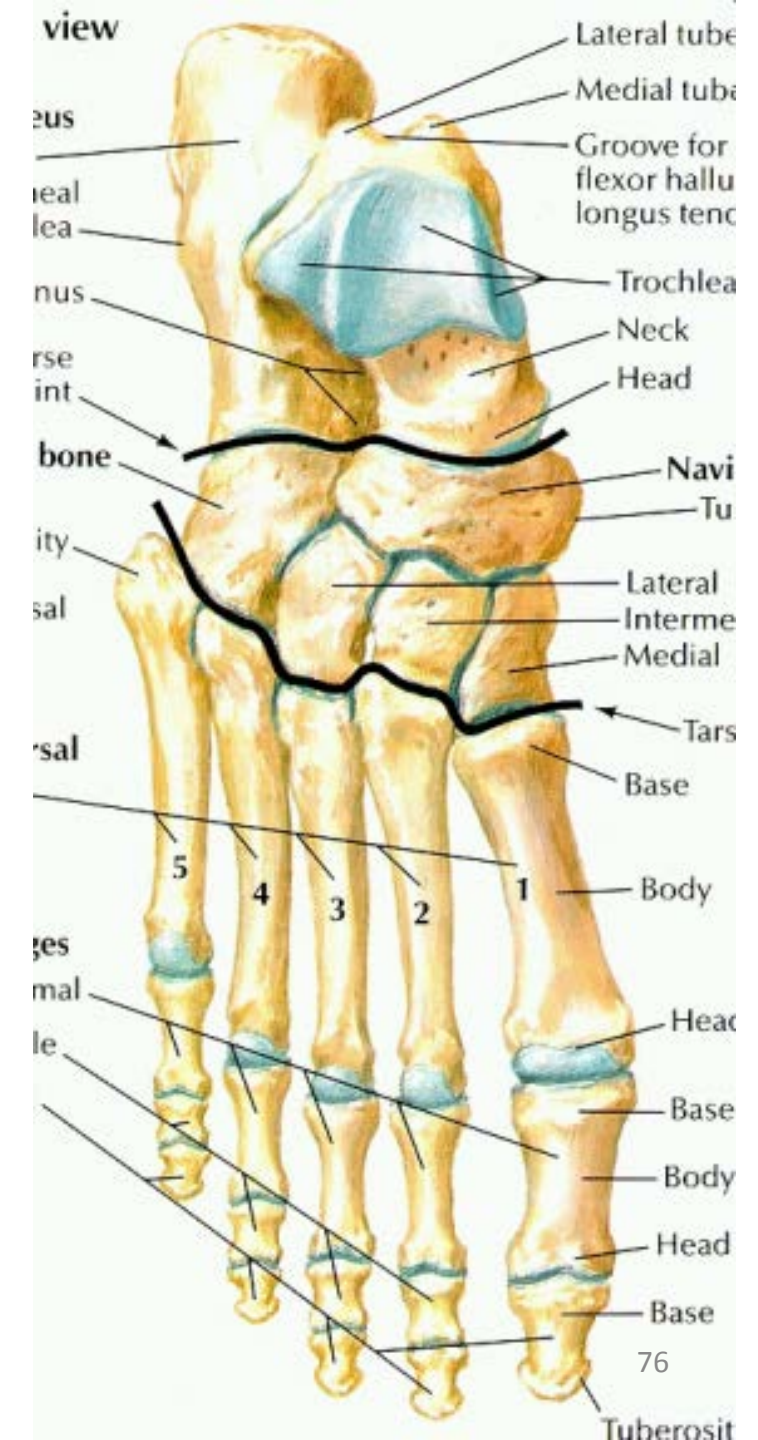
## Joint Play – Dx and Tx...

- This is about as basic a technique as you can get...
- Stabilize the proximal bone of the joint you wish to test and take the distal bone through all PROMs and articulate through any barriers.
- Many times will get an audible or palpable reduction, but recheck even if you don't...



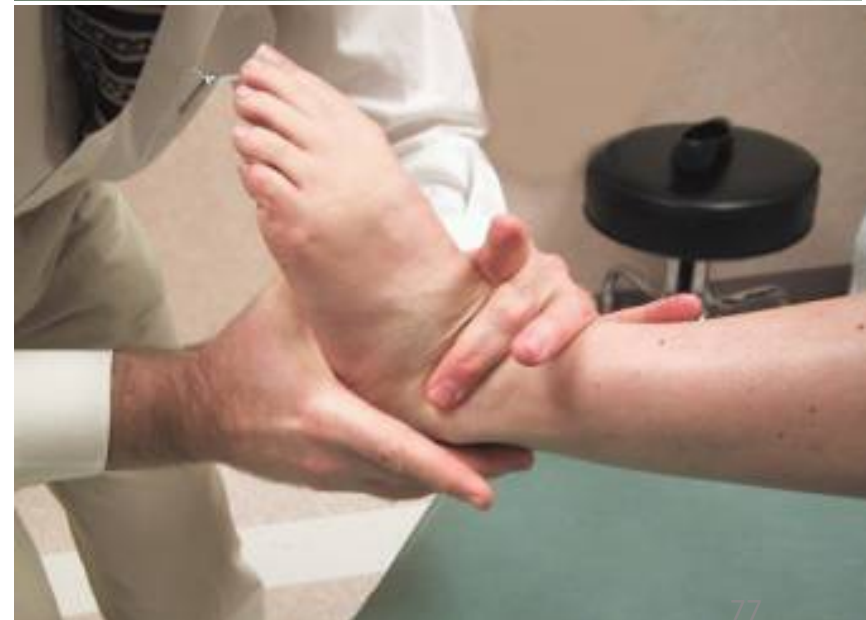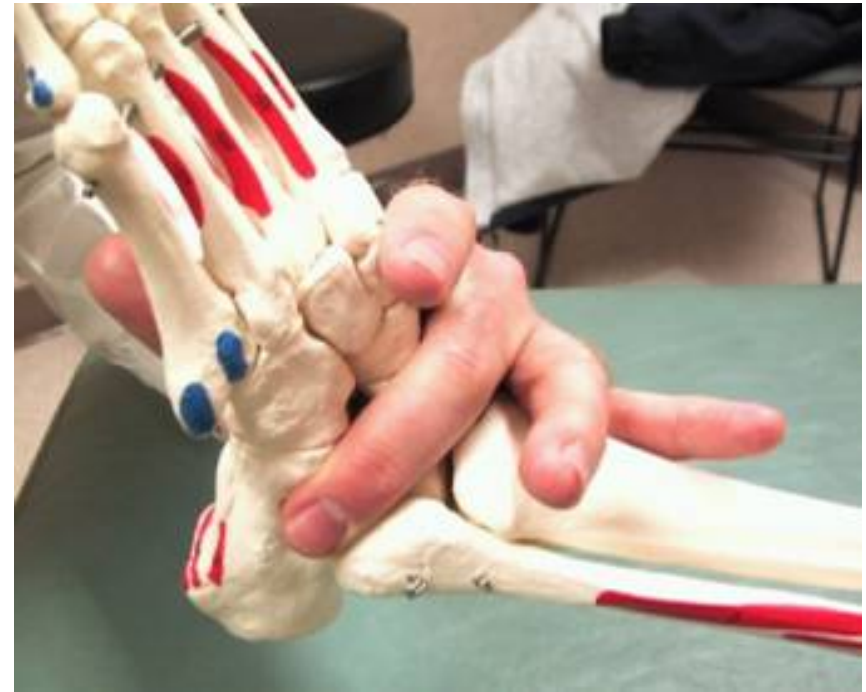# Articular Techniques for Talus

- Commonly restricted anteriorly, or impacted. ***May also present as an anterior fibular head...***
- Usually secondary to a traumatic inversion mechanism at the ankle, but can also be due to chronically tight posterior calf muscles.
- Can be associated with plantar fasciitis.
- Pt will complain of anterior talar pain or 'jamming' with attempted dorsiflexion, & possibly of reduced calf stretch when attempted.



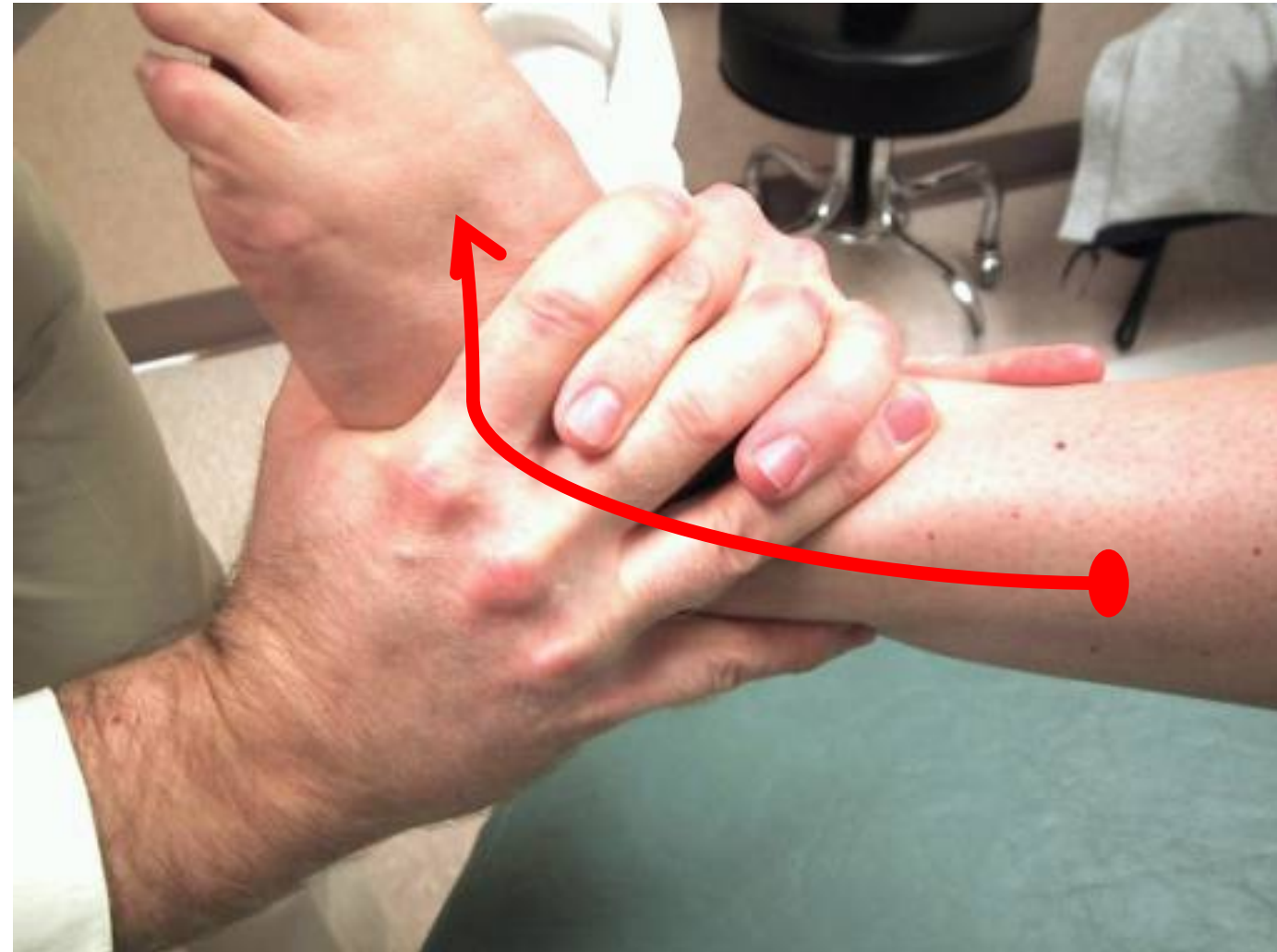# Articular Techniques for Talus

- Place ipsilateral middle or ring finger over the superior aspect of the talus, below the tib-fib joint.
- Dorsiflex ankle to the barrier, while cradling the calcaneus with the contralateral hand. You may fine tune with inversion & eversion to maximize dorsiflexion.
- With the patient relaxed, either:
  - tug the foot quickly with a moderate force in a caudal direction,
  - or with a traction force caudally, rock the calcaneus & talus as a unit in an inversion/eversion plane.



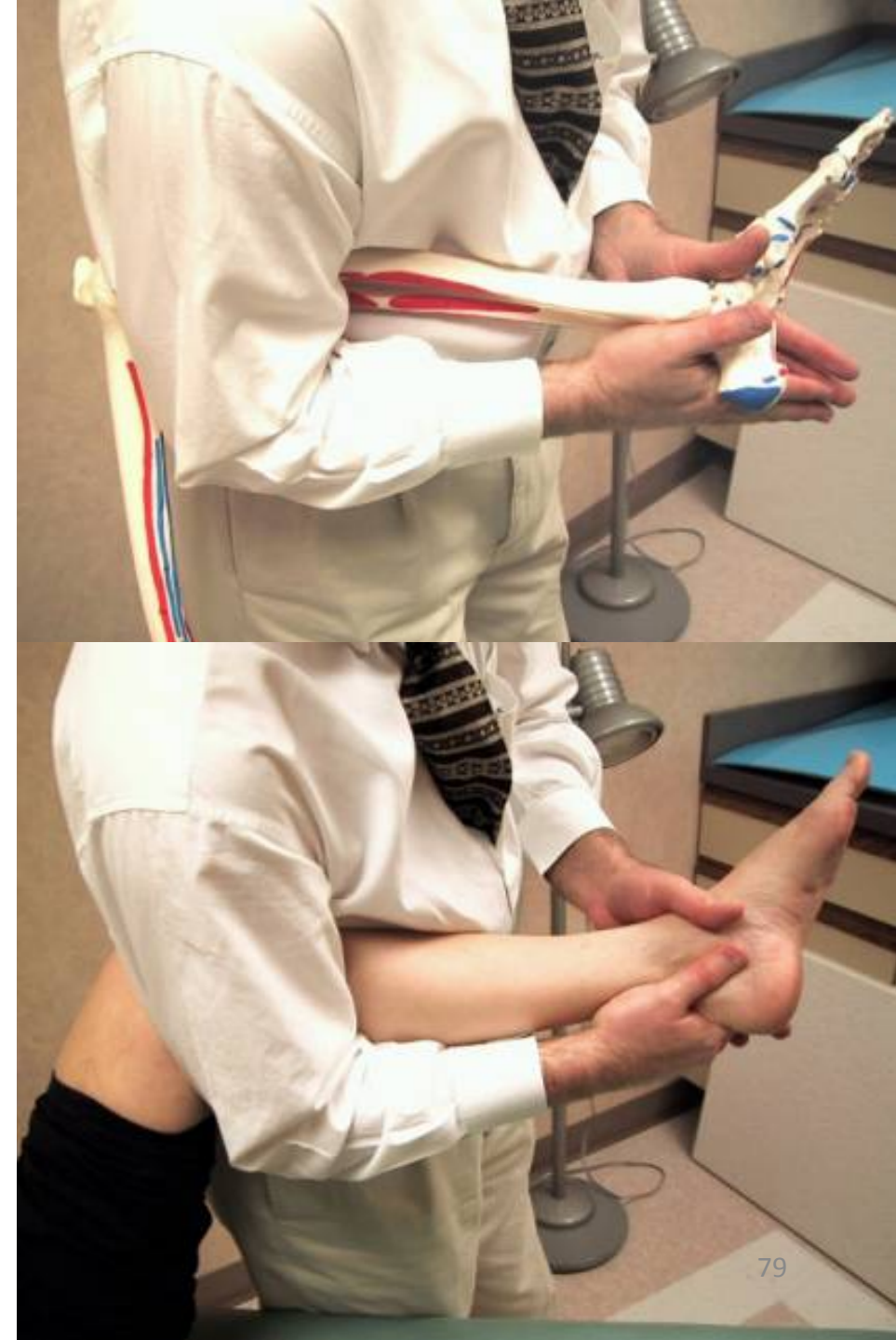## Talar Tug – Alternate Hold

- Need to pull & dorsiflex at the same time – makes a ‘J’ pattern movement when viewed this way



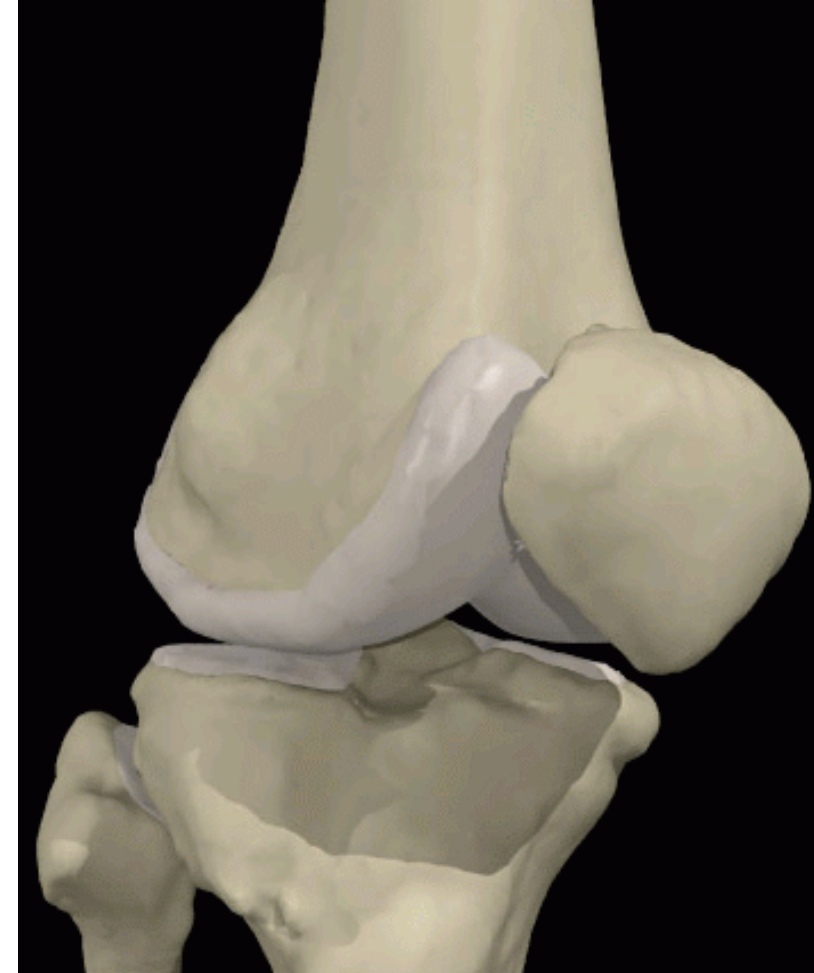# Talar Release - Articular

- Pt supine with knee & hip flexed to 90° & hip slightly abducted, nestle your elbow against the mid-hamstring area while forming a ring with your thumbs & forefingers around the talus.
- Slowly, but firmly, flex the knee while maintaining the ring around the talus. You should feel a traction force building.
- Maintaining the tension, either exert a quick thrust with the talus or gently rock the talus into dorsiflexion with a little inversion/eversion until you feel a release, pop, or clunk.



## Posterior Fibular Head - HVLA

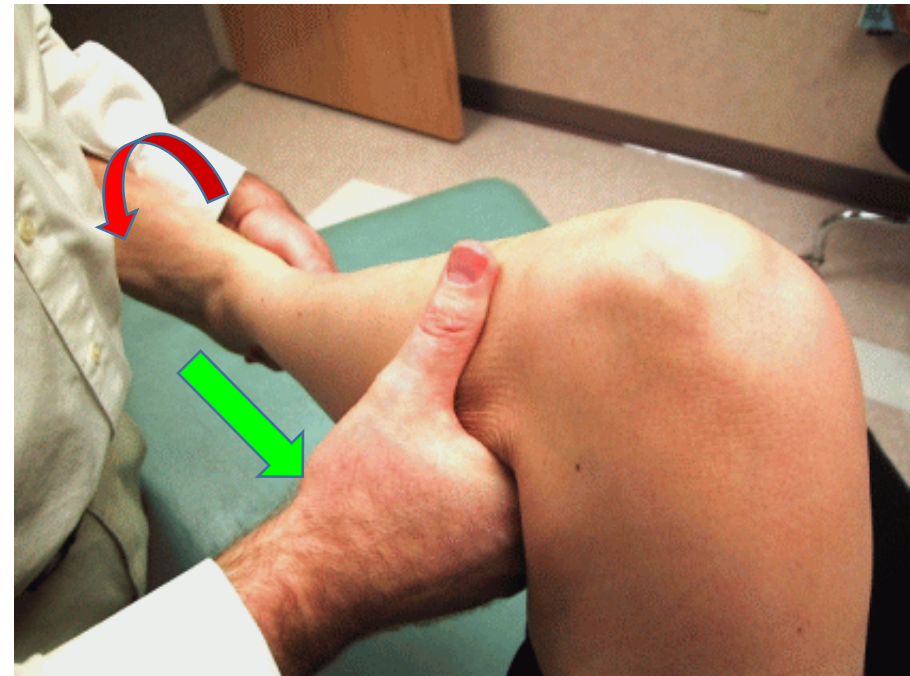
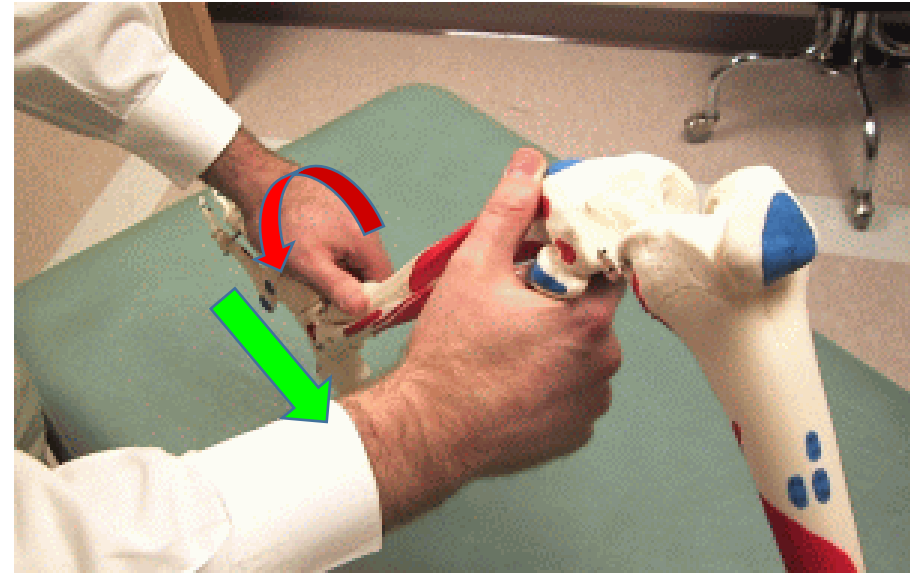
- Commonly restricted posteriorly.
- Usually secondary to a traumatic inversion mechanism at ankle.
- Can be associated w/ iliotibial tendonitis, and/or mimic lateral meniscal tears.
- Pt complains of lateral knee pain, usually w/ weightbearing & pivoting.





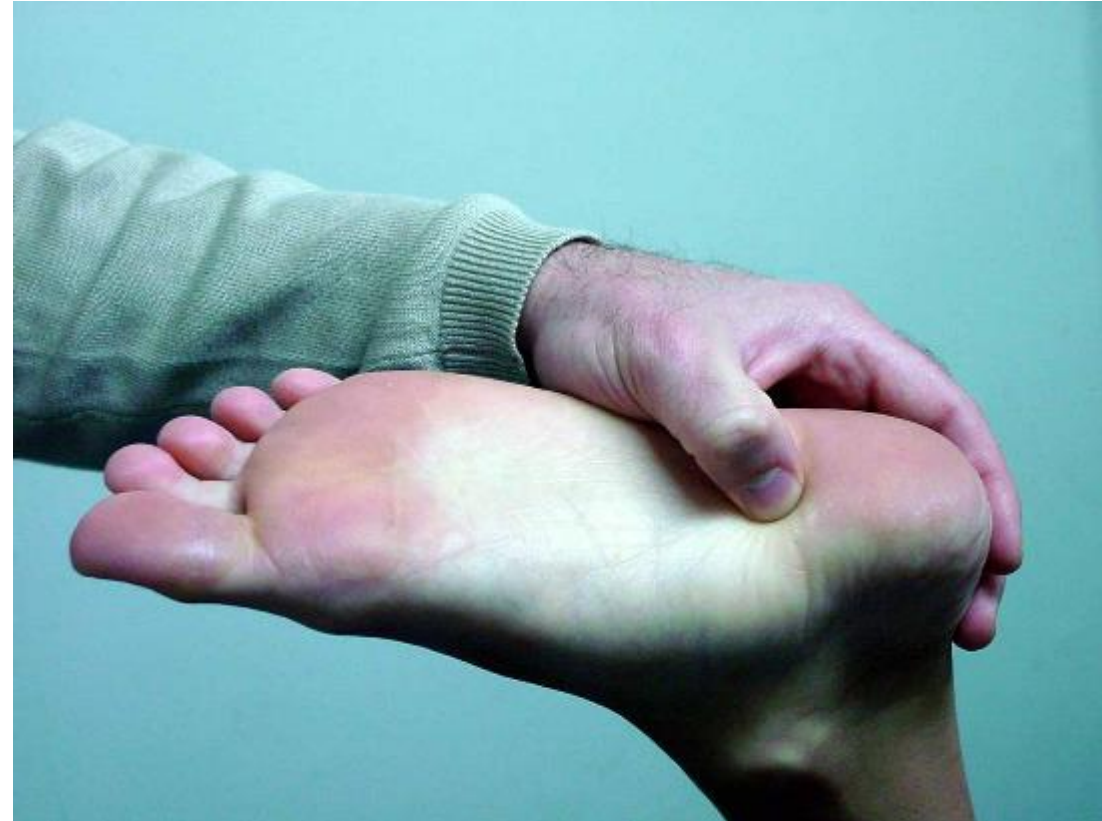## Posterior Fibular Head – LVHA / HVLA

- Grasp affected extremity w/ contralateral hand at either distal tib/fib or at calcaneus
- Ext. rotate tib to barrier (red arrow)
- Place ipsil. 2<sup>nd</sup> MCP jt behind fibular head
- Flex knee up to barrier
- Either quickly flex knee over 2<sup>nd</sup> MCP joint (green arrow), or smoothly continue flexion



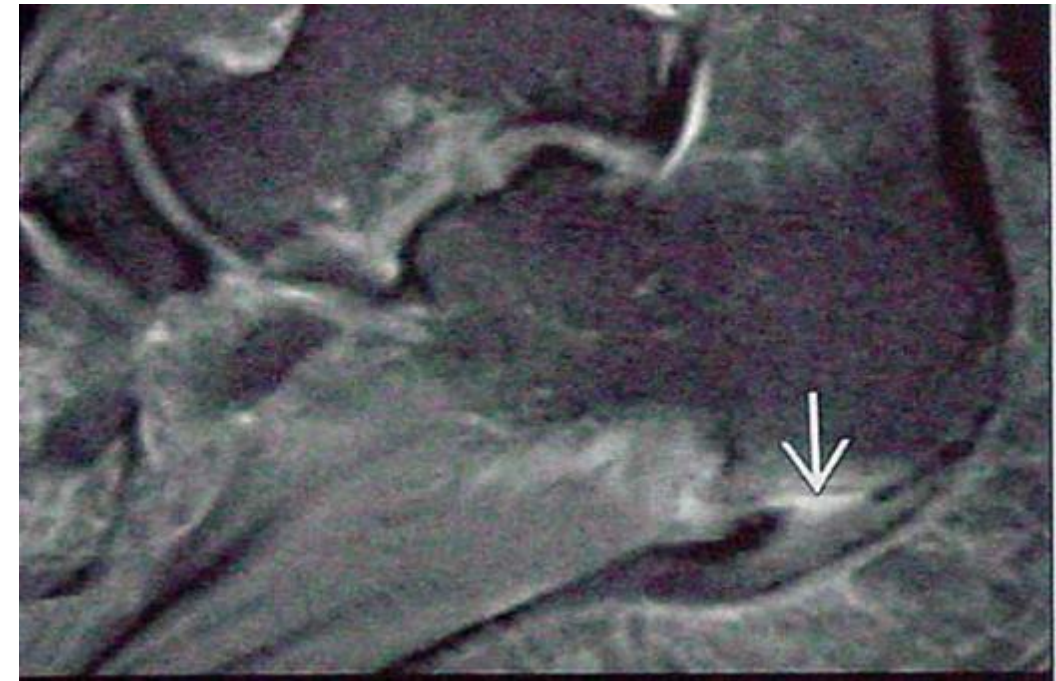# Plantar fasciitis - the problem:

- Too much tension on the plantar fascia.  
Why?
  - Arches not able to support themselves:
    - Navicular rotated
    - Weak intrinsic foot muscles
    - Weak or fatigued tibialis posterior, flexor digitorum longus, flexor hallucis longus
  - Tightness of Achilles



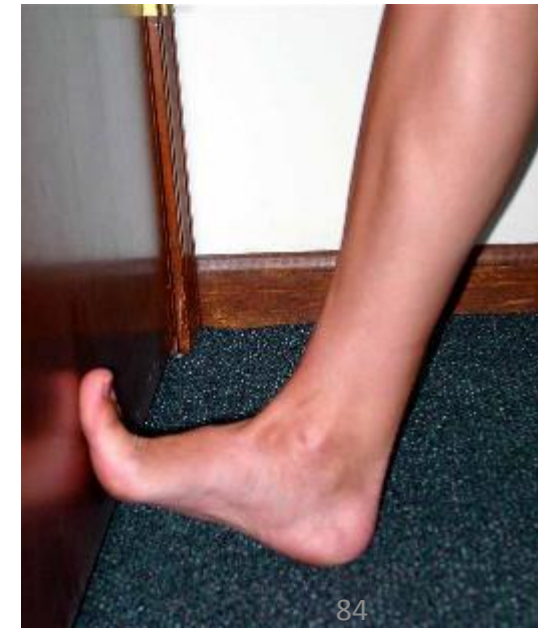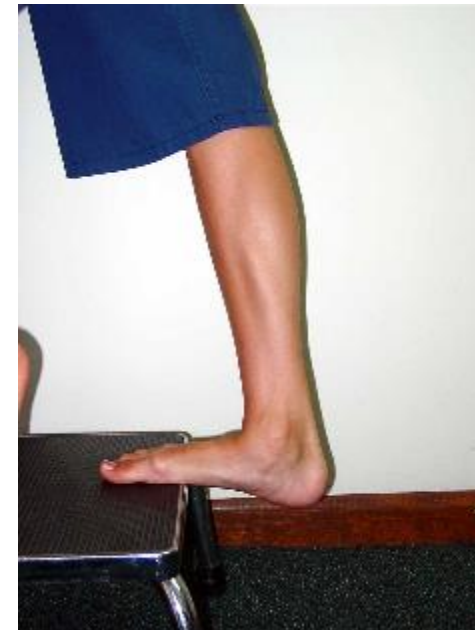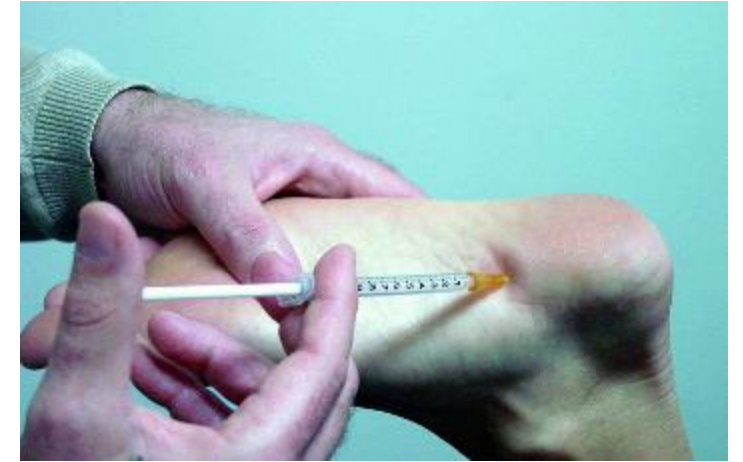## Differential diagnosis

- Fat pad contusion/atrophy
- Achilles tendonitis
- Retrocalcaneal bursitis
- Subcalcaneal bursitis
- Rupture of plantar fascia
- Medial calcaneal nerve entrapment
- Stress fracture of the calcaneus
- Tarsal tunnel syndrome (posterior tibial n.)
- Paget's disease
- S1,2 radiculopathy
- Enthesopathy (seronegative spondyloarthropathy)



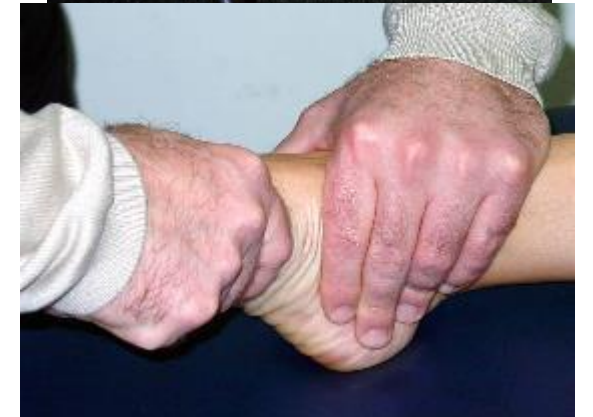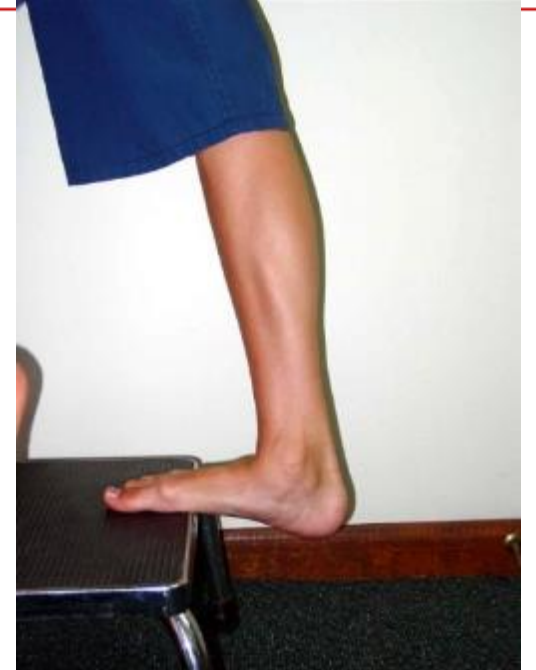
# Standard treatment

- Relative rest
- Stretching
- Intrinsic foot muscle strengthening
- Physical therapy
- Injection
- Tension night splint
- Orthotics
- Surgery

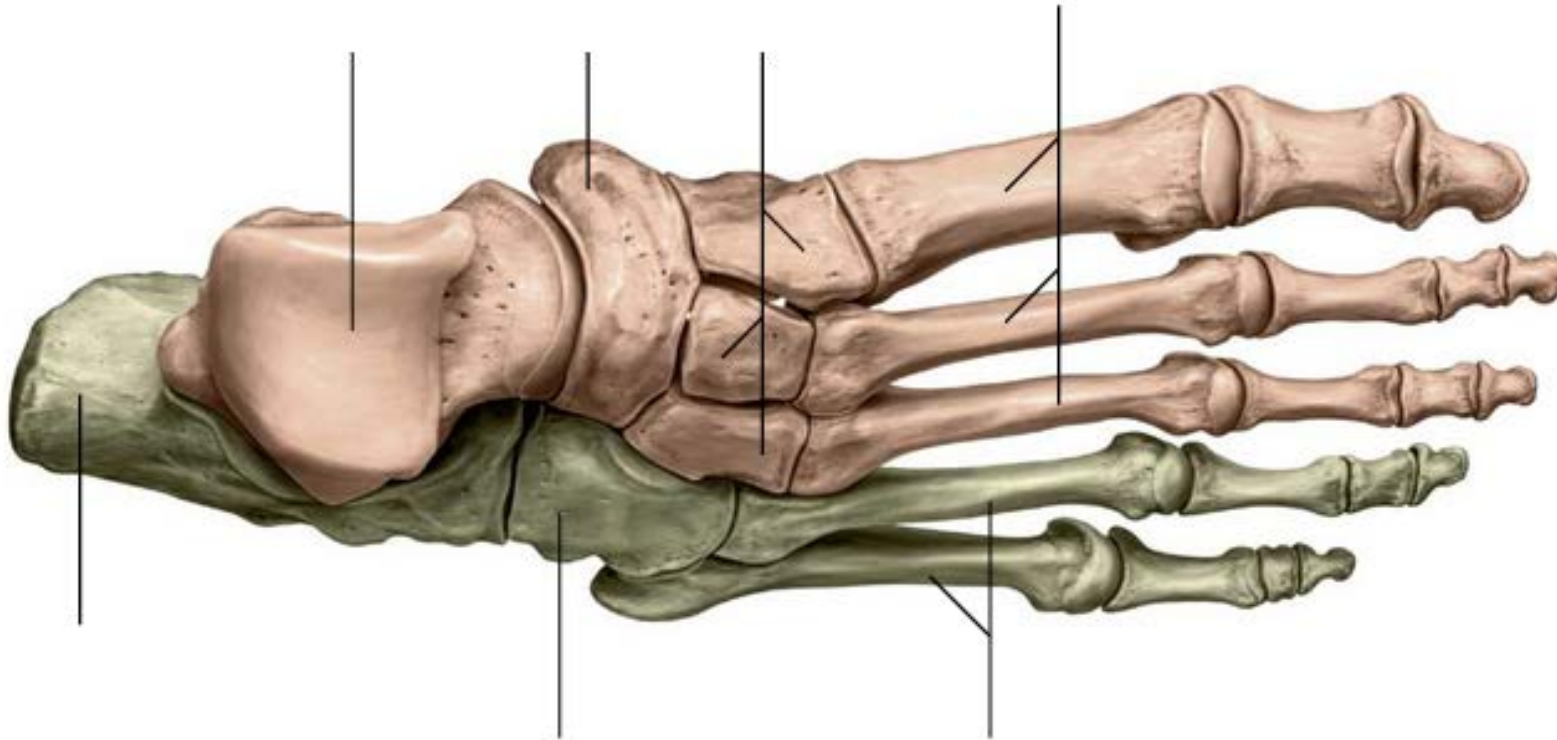


# The osteopathic advantage

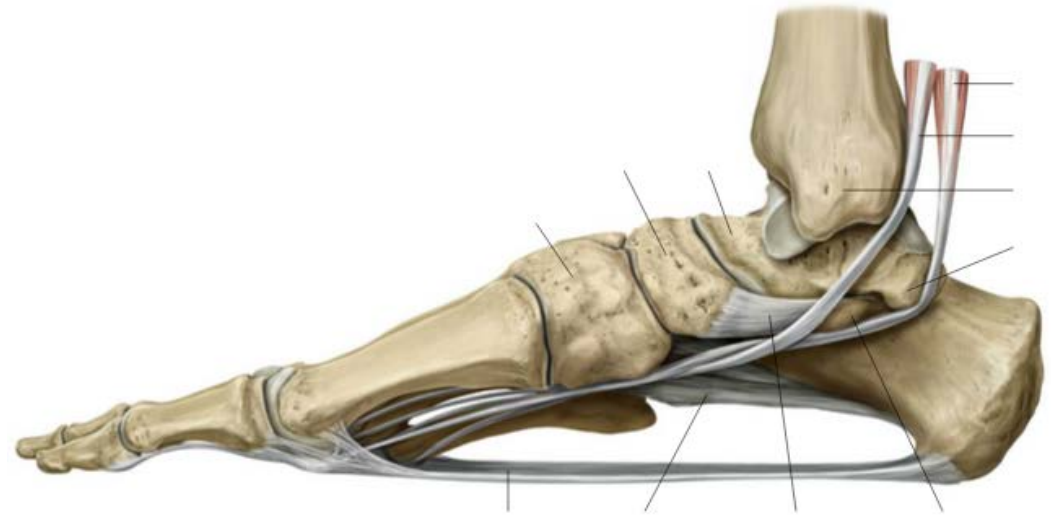
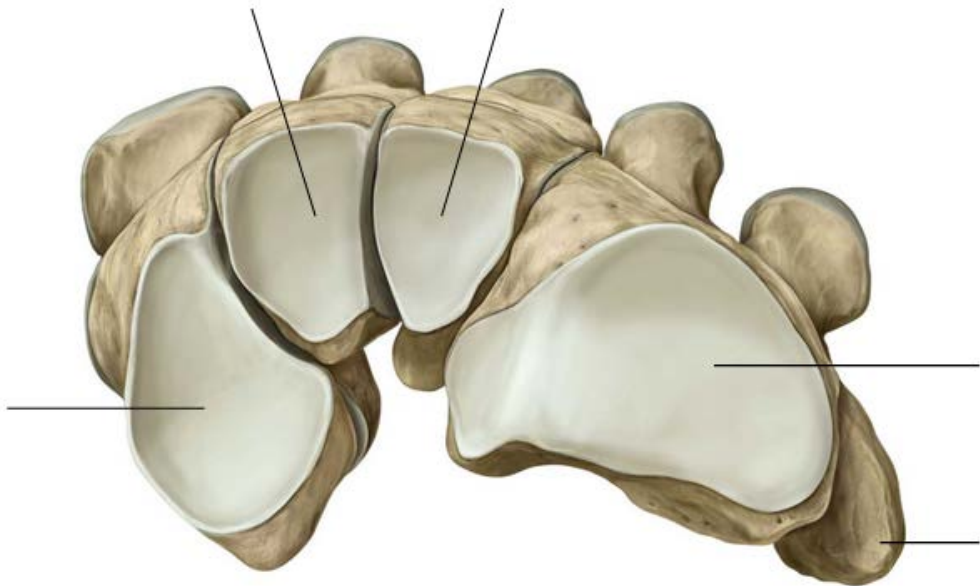
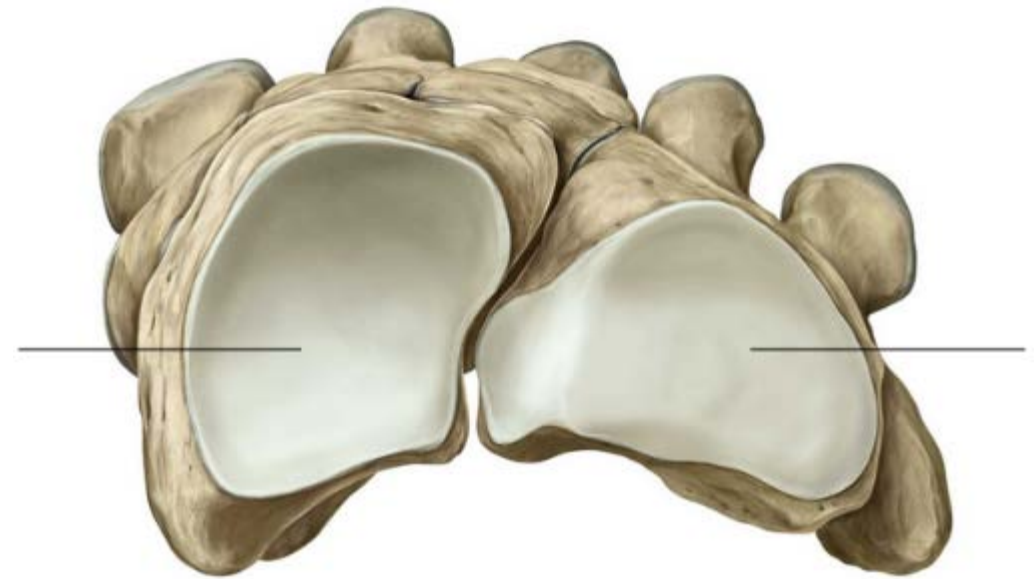
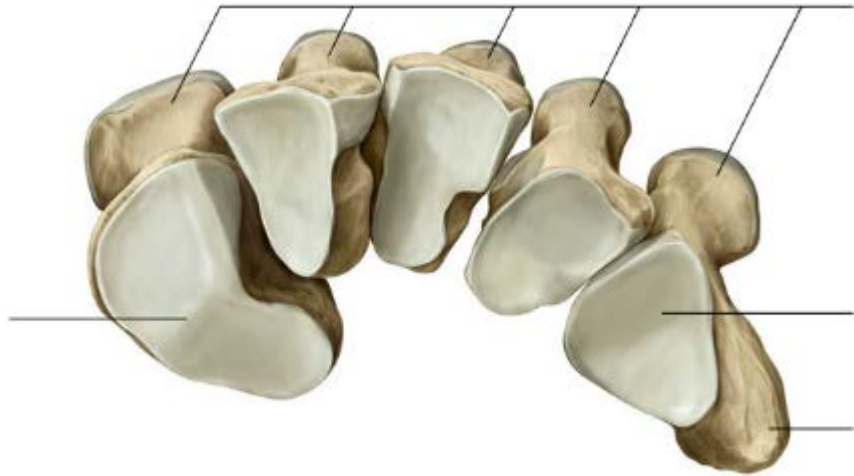- The goal of osteopathic approach must be to re-establish normal function:
  - Maintenance of the medial arch
    - Relieve pressure from the ligaments
      - OMT, arch support
    - Improve strength of intrinsic foot muscles
      - exercises
    - Correct tightness of the Achilles
      - OMT, stretching
    - Improve proprioceptive function
      - OMT, specific proprioceptive retraining
- *But don't forget that there is still pathology that must heal!*



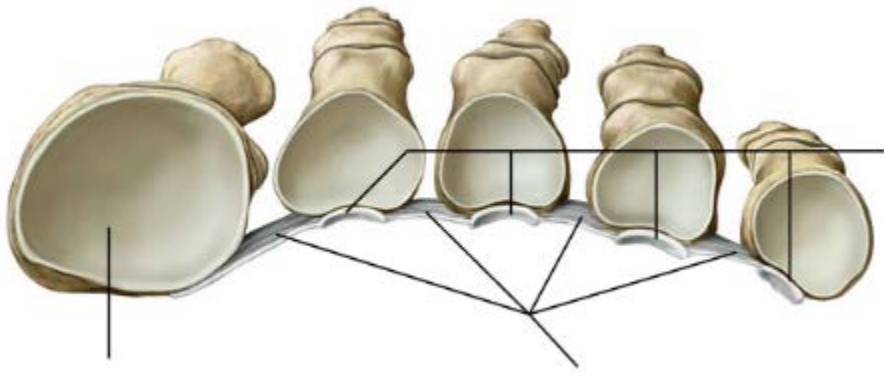
# Two arches to the foot



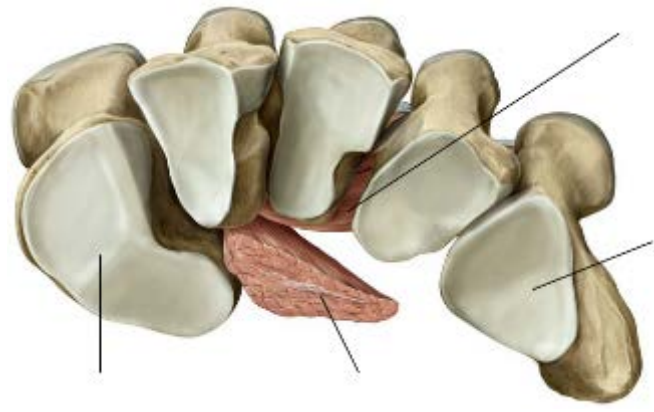# Arches



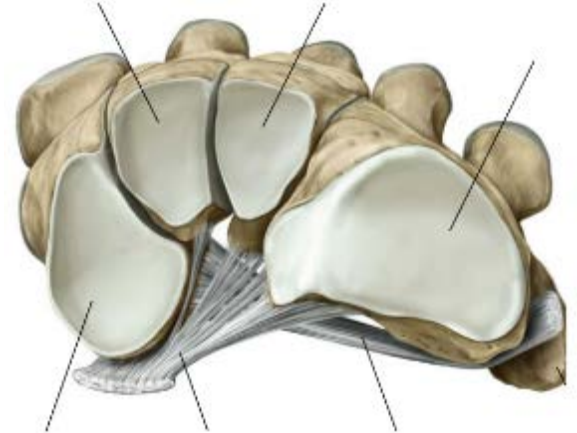
# Transverse Arch Supports



Passive at forefoot



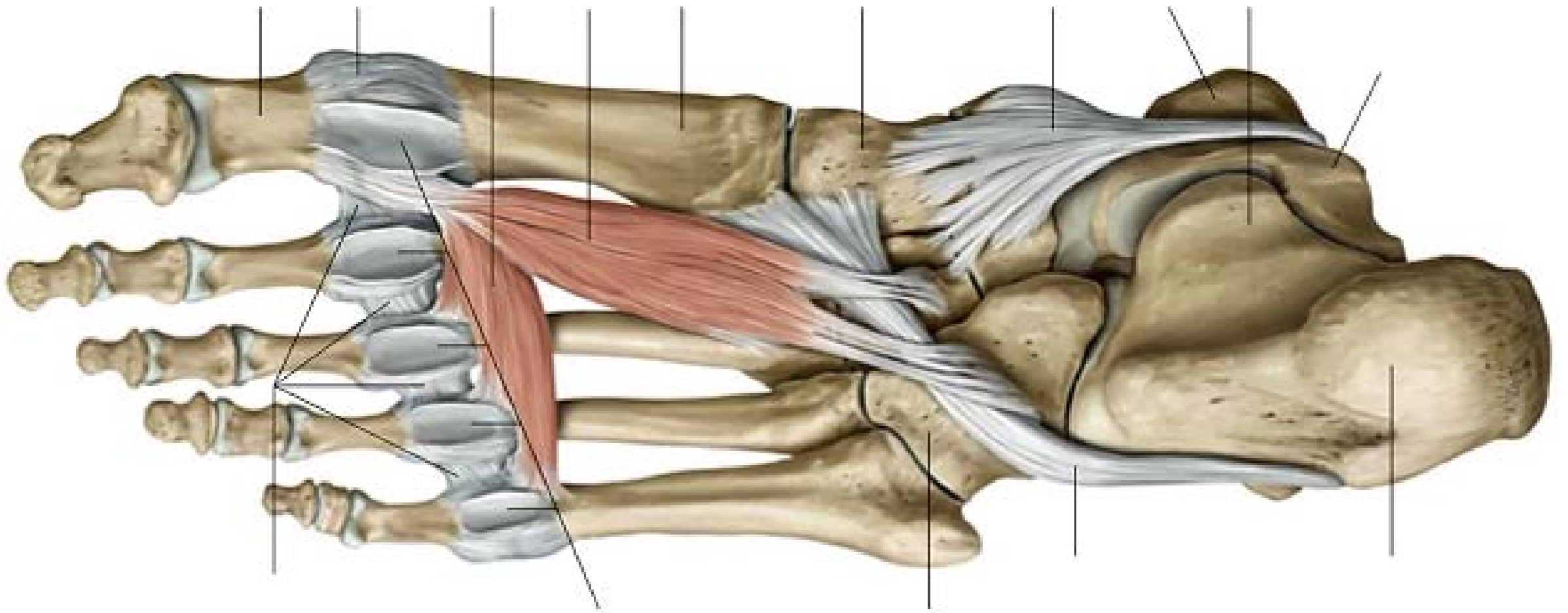
Active at midfoot



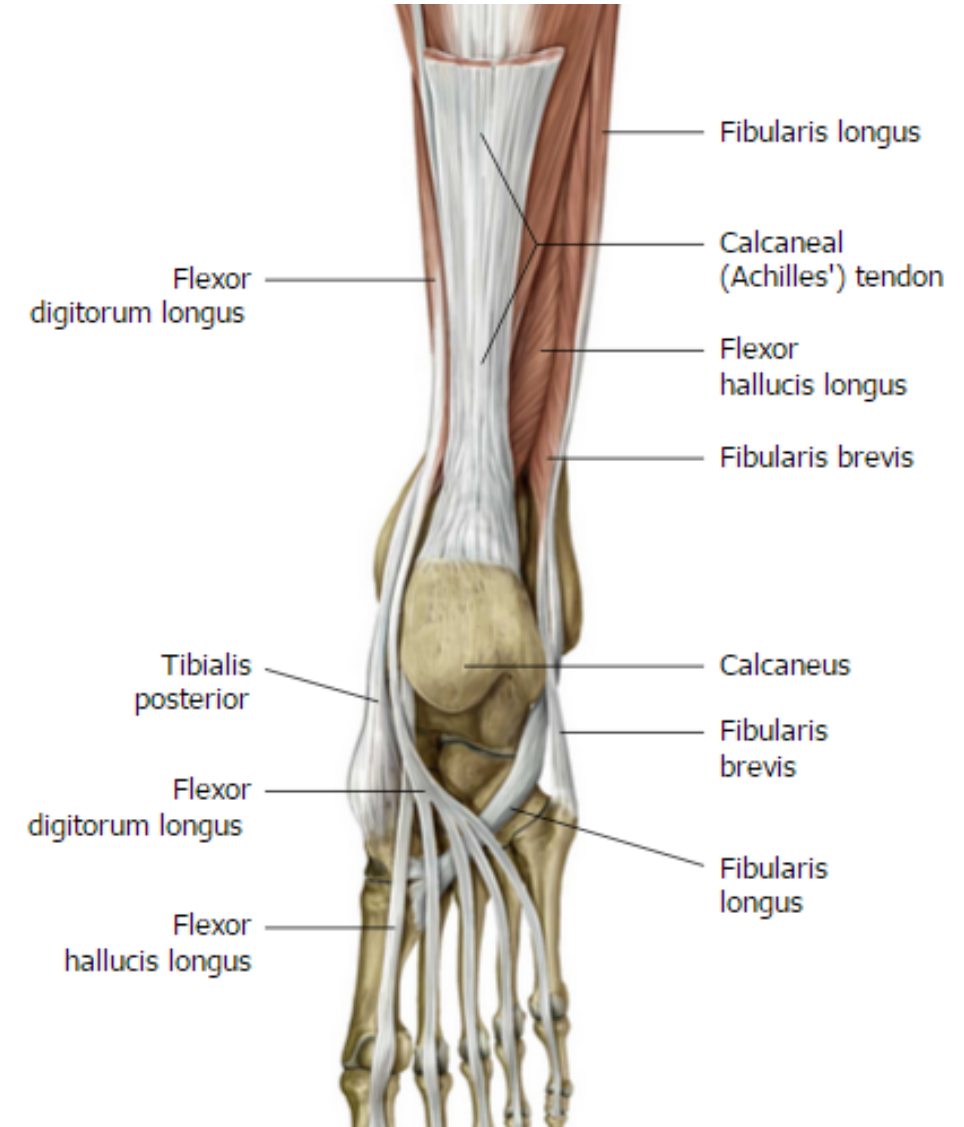
Active at midfoot



# Transverse Arch Supports



Tibialis posterior  
Flexor hallucis longus  
Flexor digitorum longus  
Fibularis brevis  
Fibularis longus



# The treatment

- Regardless of how you choose to affect the problem, certain things must be consistently done in order to treat the problem, and prevent its recurrence.
  - Remember that there is pathology here.
- Inquire regarding changes in activity, footwear:
  - Often patients present after it has been present for months—ask specifically.
  - Look at the shoes and the insoles.

# Common aspects of treatment

- You must take pressure off the plantar fascia:
  - Easiest way to do this is with a heel lift:
    - Typically 5-10mm is sufficient.
  - Treat both sides.
- Stretch the Achilles tendon, both gastroc & soleus.
- Stretch the plantar fascia.
- Strengthen the intrinsic foot muscles.

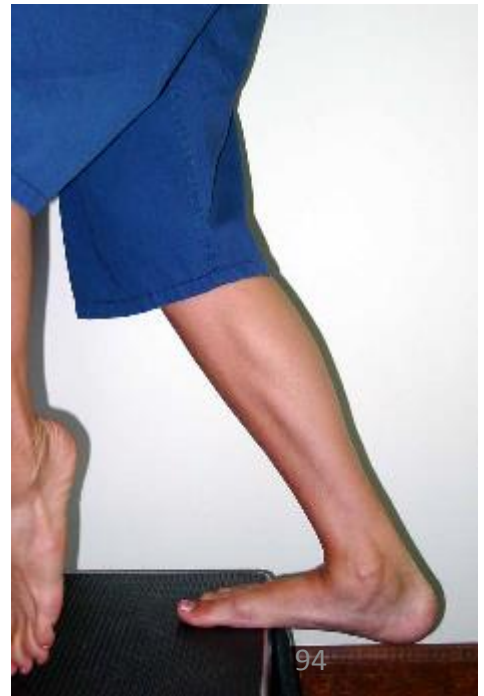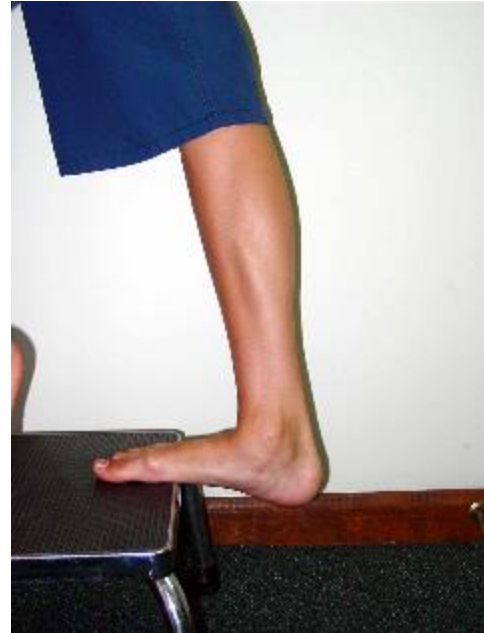# Unload the plantar fascia

- Critical to relieve tension on plantar fascia.
- Can be done multiple ways, but heel lift is often easiest:
  - This drops the forefoot during weight bearing, shortening the distance between the metatarsals and calcaneus
  - Secondarily relieves tension on Achilles
- Should be done from a horizontal, not sloping (such as a high-heeled shoe would do), position.



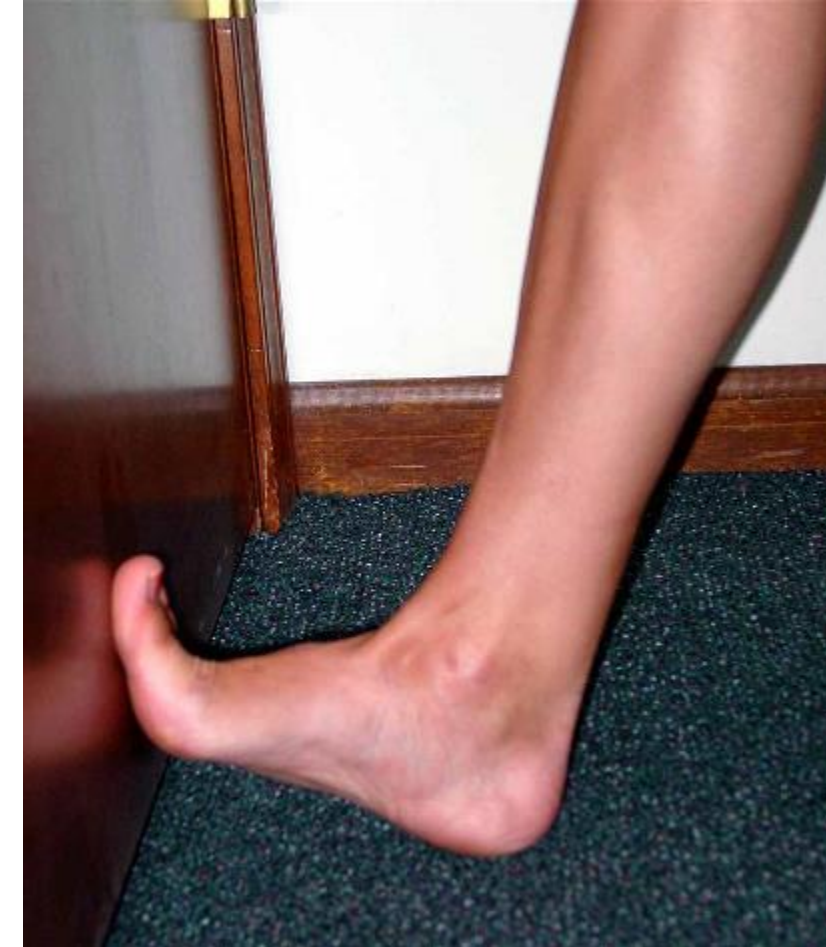# Stretch the Achilles tendon

- Possibly the most important aspect of treatment.
- Remember to stretch both gastroc (knee straight) & soleus (knee bent)
- Stretches should be held for 20-30s, repeated three times, both sides, regardless of symptoms.
- Consider using a step &/or activated stretching (muscle energy)



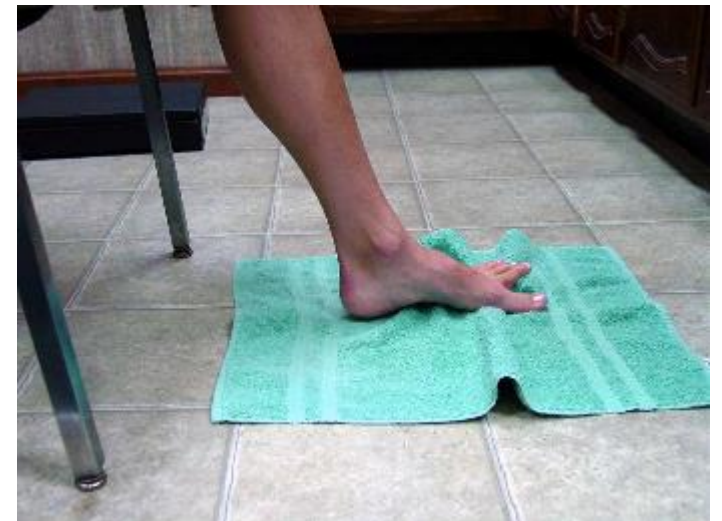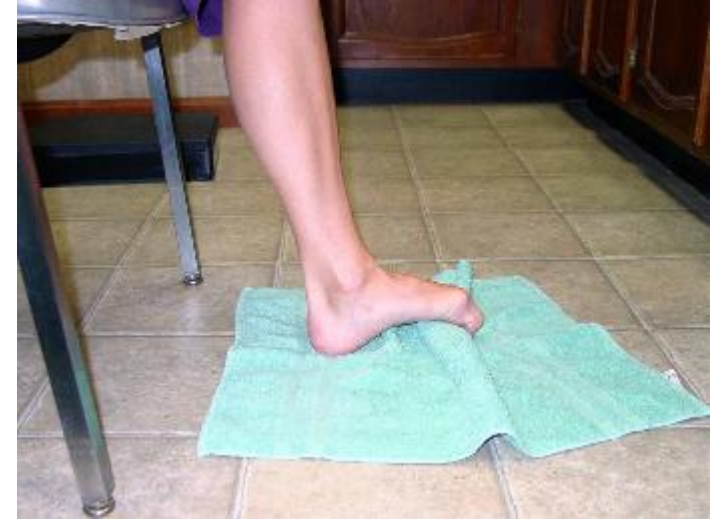# Plantar fascia stretch

- Direct stretching of plantar fascia is often recommended
- I am not always sure how beneficial this is, or if the therapeutic benefit is really in stretching the fascia, or in some of the associated muscles supporting the arch.
- Stretch held same as previous ones.



# Strengthen intrinsic foot muscles

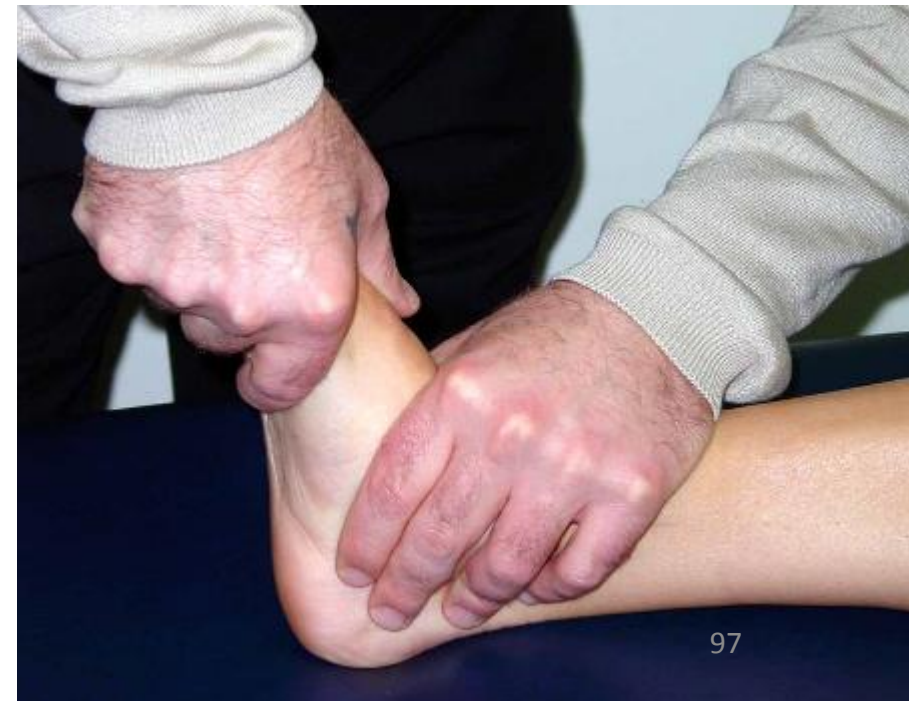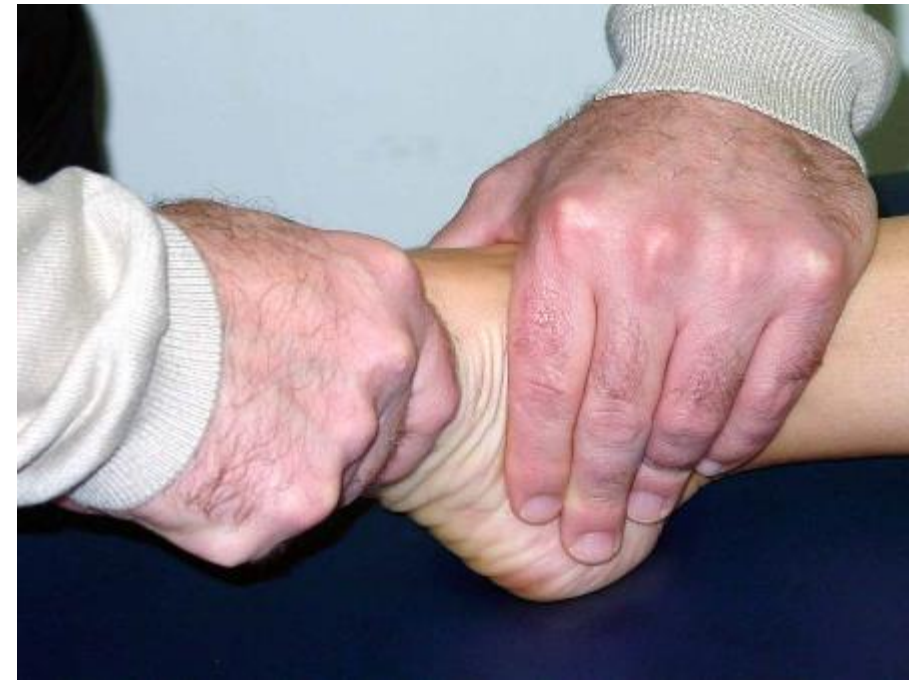- I find this very helpful in reconditioning muscles to help support the arch.
- Does more than just intrinsic muscles, also includes the flexor hallucis longus, flexor digitorum longus, and maybe tibialis posterior.





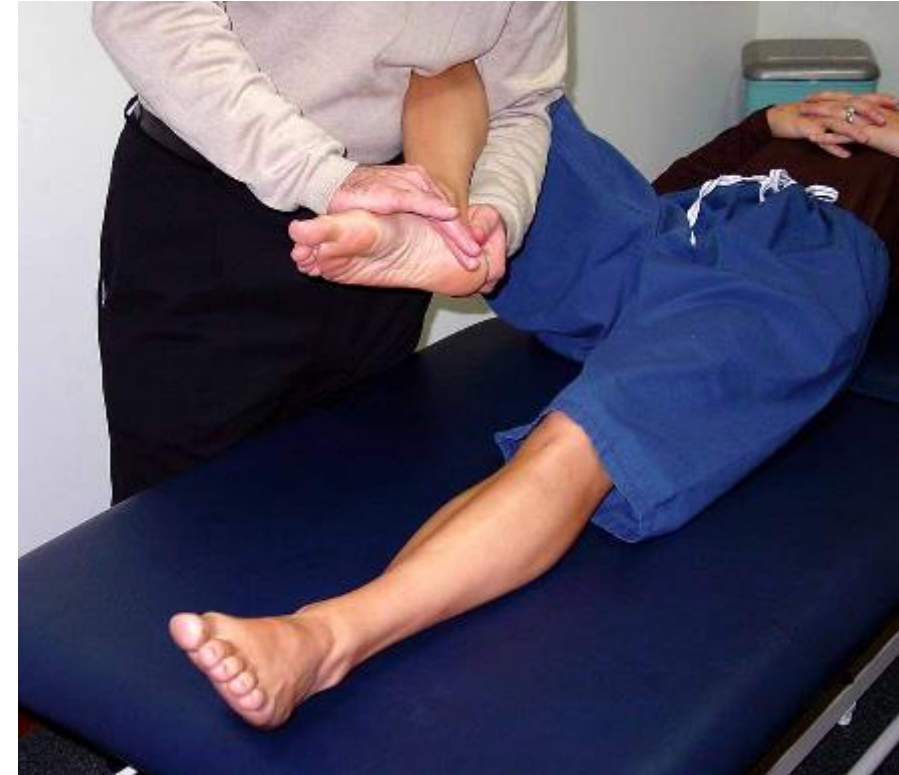# OMT: navicular/cuboid

- Correct dysfunction of the arch, especially the navicular, which tends to be rotated medially.
- Functional approach:
  - Start from position of ease.
  - Add compressive force.
  - Take joint to, and through, the original barrier, maintaining the compressive force.



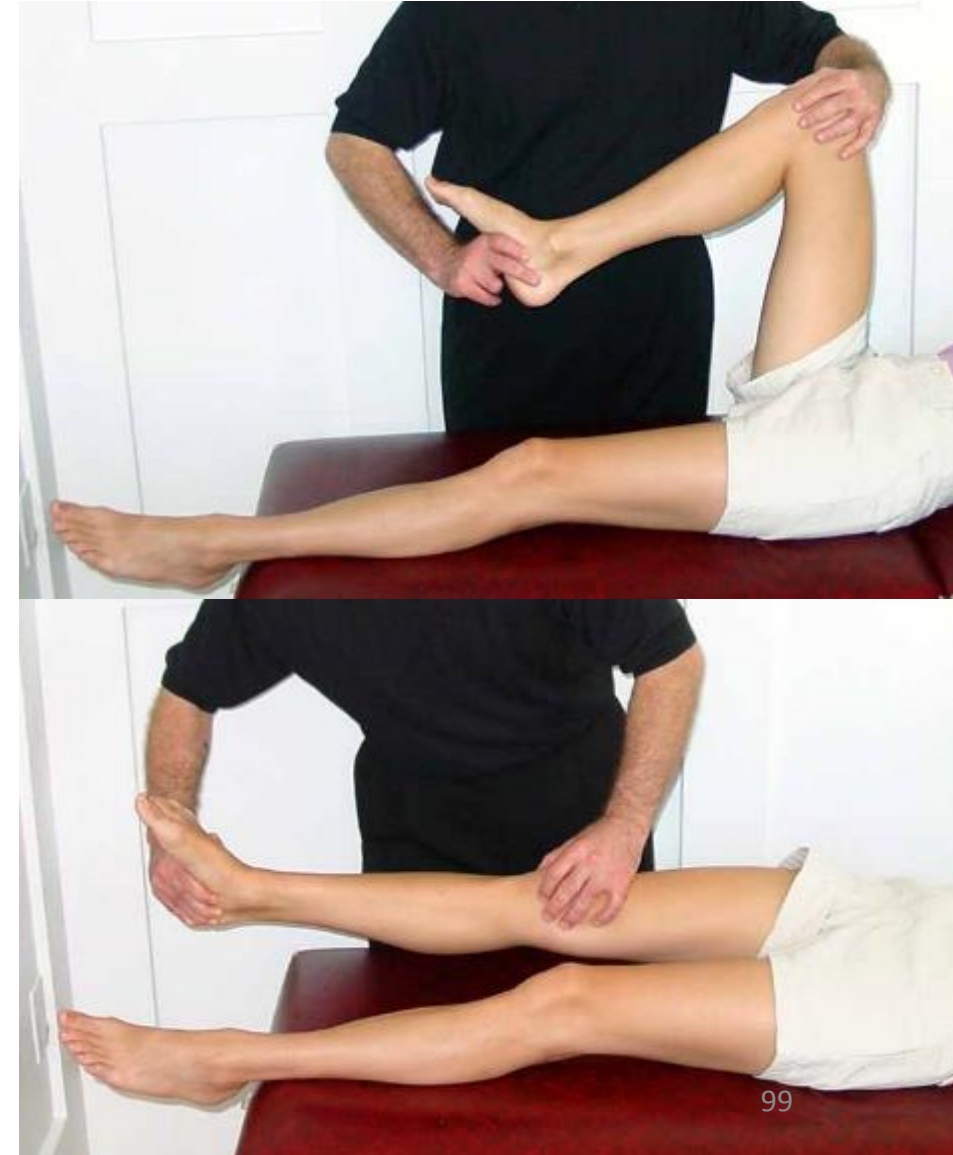# OMT: tibiotalar joint – already did this

- Often also restricted with talus held in relatively valgus position.
- Many ways to do this: this is an articulatory technique:
  - Contralateral elbow in popliteal fossa
  - Hand grasp calcaneus and anterior process of talus.
  - Lean cephalad, elbow acting as fulcrum to distract the talus from the mortise.
  - Gently rock the talus until articulation and release occurs.



# OMT: tibial torsion

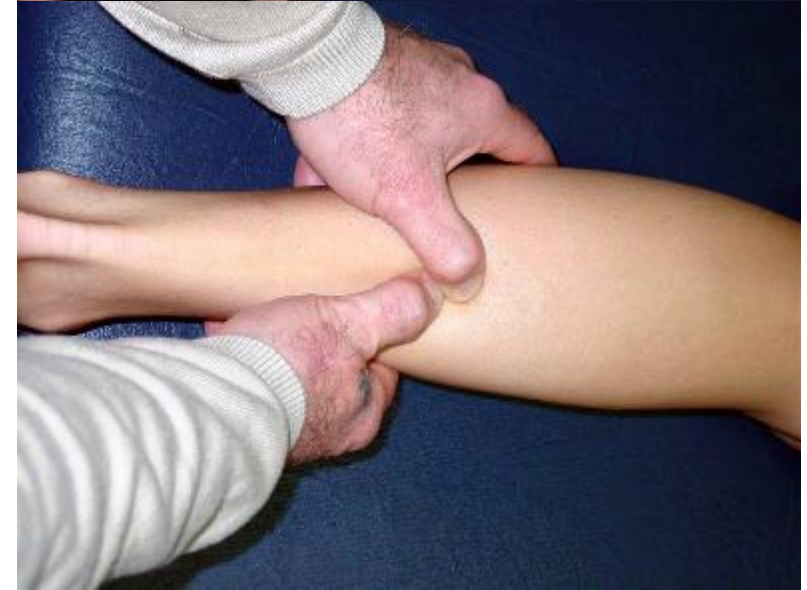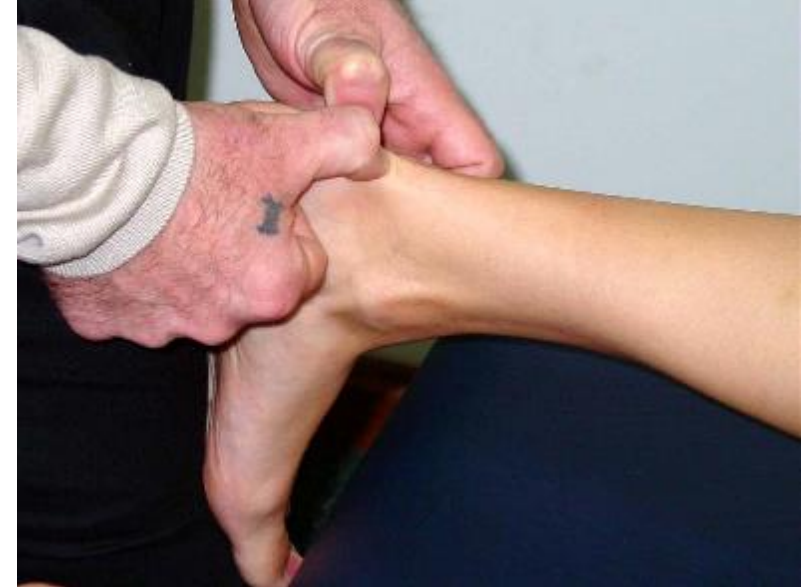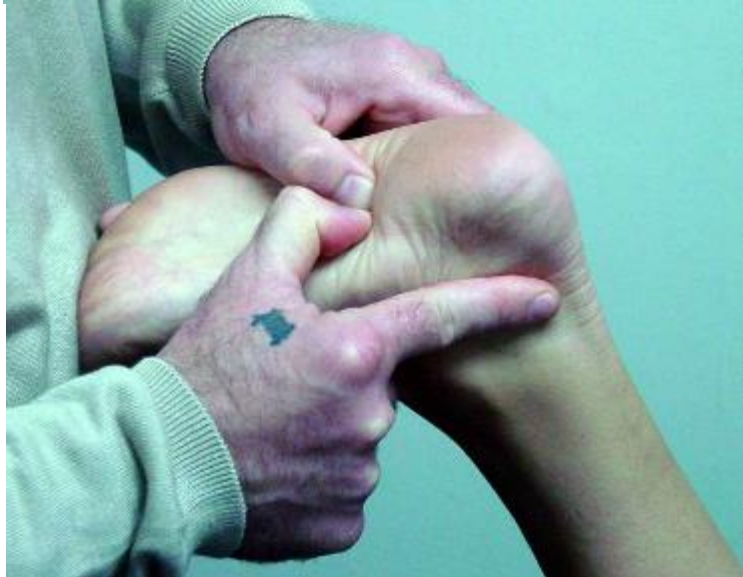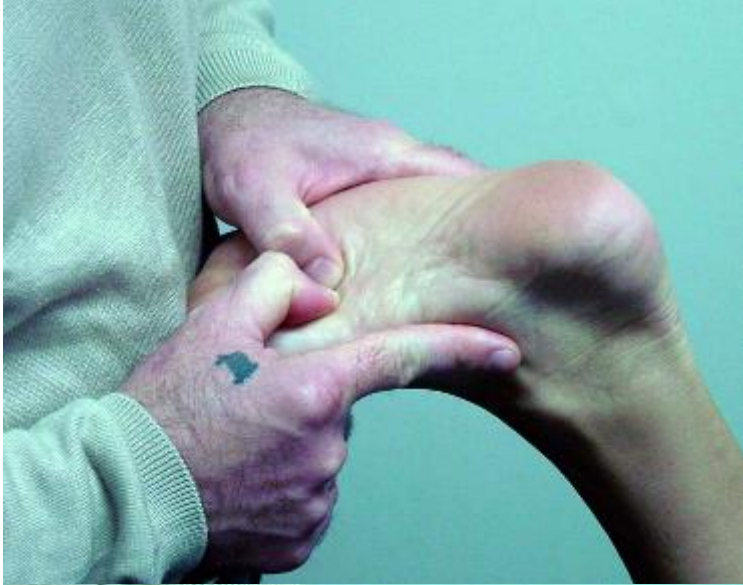- Notice that we are working up the kinetic chain. Obviously any somatic dysfunction should be treated, especially in lumbar, sacrum, & pelvis.
- Functional technique:
  - Start from position of ease, typically ext rot.
  - Apply compressive force up to knee.
  - Move tibia to and through barrier while extending the knee.



# Fascial stripping (Fascial Distortion Model Technique)

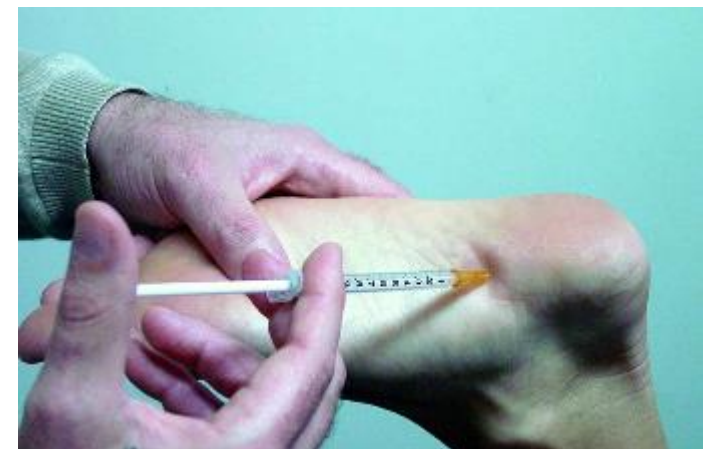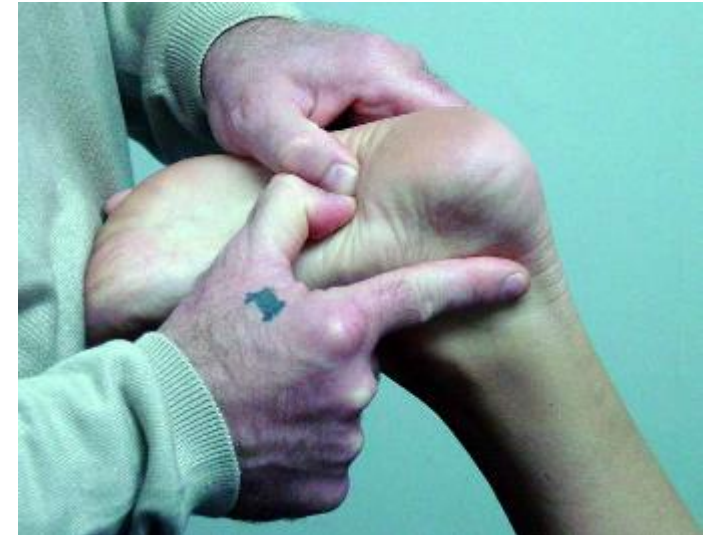- This is something that has been modified from Steven Typaldos, DO.
- It is very painful, but very effective, and they often stand up feeling much better.
- Treatment is done once per week, and typically takes ~6 treatments, sometimes less.

# Fascial stripping



# So what do we do?

- Make sure it is plantar fasciitis!
- Treat the existing somatic dysfunction on the first visit.
- Heel lift.
- HEP consisting of stretching & strengthening as described.
- Then either:
  - Fascial stripping protocol
  - Injection protocol



# References – including images

1. <http://themethuselahcenter.com/wp-content/uploads/2011/07/poor-posture.jpg>
2. <http://www.platinumphysio.co.uk/patient-info/conditions-treated/head-neck/>
3. <http://davidlasnier.com/2012/overhead-work-and-shoulder-flexion-limitation>
4. <http://rpm-therapy.com/wp-content/uploads/2012/09/hairdresser-posture-bad3.jpg>
5. <http://rpm-therapy.com/wp-content/uploads/2012/09/hairdresser-posture-bad.jpg>
6. Thieme, Atlas of Anatomy, 2nd ed. Fig. 39.5 C.
7. <http://www.muscleimbalancesyndromes.com/janda-syndromes/upper-crossed-syndrome/>
8. [http://karenoosterbaan.com/wp-content/uploads/2012/11/David\\_Yu\\_feature\\_alexander\\_technique\\_t6301.jpg](http://karenoosterbaan.com/wp-content/uploads/2012/11/David_Yu_feature_alexander_technique_t6301.jpg)
9. [http://assets.nydailynews.com/polopoly\\_fs/1.474670!/img/httpImage/image.jpg\\_gen/derivatives/article\\_970/alg-rangers-lee-motion-jpg.jpg](http://assets.nydailynews.com/polopoly_fs/1.474670!/img/httpImage/image.jpg_gen/derivatives/article_970/alg-rangers-lee-motion-jpg.jpg)
10. Valley Morning Star article – Friday, July 29, 1938, pg.11
11. Karageanes, S & et al. *Principles of Manual Sports Medicine*. Lippincott, Williams & Wilkins; 2004. Multiple images used with written permission of editor - Steven Karageanes, DO, FAOASM.
12. DiGiovanna, Schiowitz, & Dowling. *An Osteopathic Approach to Diagnosis & Treatment, 3<sup>rd</sup> ed.*

# Credits

## Special thanks to :

- Beverly Goodwillie, RN
- Debbie Verkin, LD, RD – Peds
- Rhonda Price
- Michael Sampson, DO,  
FAOASM
- Fran Adkins, OMS-IV
- Bren Nolan, OMS-IV
- Abby Huck, OMS-IV
- Zach Daniels, OMS-II
- Mark Riley, OMS-II
- Jesse Sheldon, OMS-II
- Shannon Flahive, OMS-I